

Clinical Characterization of Surgical Opportunities in Proliferative Diabetic Retinopathy - A Population-Based Study

Wang Tao^{1,*}, Liu Chao²

¹Department of Ophthalmology, Ding Zhou Tian Shun Eye Hospital, Baoding, China

²Department of Surgery, Clinical Medicine, Universitas Prima Indonesia, Medan, Indonesia

Email address:

wangtaok2023@163.com (Wang Tao), 13183290311@163.com (Wang Tao), liuchao1838044@163.com (Liu Chao)

*Corresponding author

To cite this article:

Wang Tao, Liu Chao. Clinical Characterization of Surgical Opportunities in Proliferative Diabetic Retinopathy - A Population-Based Study. *International Journal of Ophthalmology & Visual Science*. Vol. 8, No. 4, 2023, pp. 48-52. doi: 10.11648/j.ijovs.20230804.11

Received: October 14, 2023; **Accepted:** October 27, 2023; **Published:** November 9, 2023

Abstract: *Background:* Proliferative diabetic retinopathy is the most common complication of diabetes. Long-term high blood sugar damage to retinal blood vessels, including arteriosclerosis, tissue ischemia, hypoxia, compensatory neovascularization and other pathological changes. It is divided into non-proliferative period and proliferative period. Then the treatment is to control blood sugar and take medicine to treat it conservatively. When vision declines, eyeball changes and retinopathy reach a certain level, when surgery is particularly critical. Early surgical treatment is not enough. The late operation misses the opportunity, which affects the effect of surgical treatment and even aggravates the condition. At present, the timing of the operation is still controversial. It is necessary to study the clinical characteristic analysis of surgical opportunities for proliferative diabetic retinopathy. The research will explain the advantages and disadvantages and the research results. *Research methods:* Vitrectomy was performed on 66 patients (89 eyes) with PDR hospitalized from January 2020 to January 2023. During the operation, different surgical treatment methods were used according to the situation, so that the omentum was well restored. Patients were followed up after surgical treatment. This includes improvement in corrected vision after 3 months, 6 months, and 12 months, no improvement or decline in vision, and loss of eye vision. In the clinical study, the improvement of visual acuity in stage IV to V, the treatment of intraocular filling with silicone oil, etc. Statistical analysis and clinical characteristics were conducted based on the above data. *Objective:* To study and explore the clinical characteristics of surgical opportunities after retinopathy caused by diabetic complications. *Results:* Vitrectomy was performed on 66 patients (89 eyes) with PDR who were hospitalized between January 2020 and January 2023. During the operation, 15 eyes were treated with peeling membrane, 20 eyes were treated with retinal photocoagulation, 17 eyes were treated with gas-liquid exchange or heavy water injection, and 37 eyes were treated with C3F8 gas or silicone oil filling. Results After 3 months, 6 months and 12 months, 68 eyes were improved, 12 eyes were not improved or decreased, and 9 eyes were lost. Stage IV-V 65 eyes (stage V 31 eyes), stage VI 24 eyes. Postoperative visual acuity improved in 45 eyes in stage IV to V and 12 eyes in stage VI. 37 eyes filled with silicone oil. Stage IV to stage V 25 eyes, stage VI 12 eyes.

Keywords: Diabetes, Diabetes Complications, Retinopathy, Surgical Treatment, Vitrectomy, Vision Correction, Access to Surgery, Loss of Vision

1. Introduction

At present, the true pathogenesis of PDR is still unknown, and PDR has become a major blinding eye disease among blinding diseases. PDR combined with severe vitreous hemorrhage, secondary traction retinal detachment and

neovascular glaucoma are the root causes of blindness in diabetic patients [1]. Laser therapy and vitreous surgery are effective treatments for PDR. Treatment options can preserve original visual function and reduce the risk of vision loss [2].

In clinical ophthalmologist's understanding and treatment of PDR in different periods, as well as grasping the opportunities and indications of vitreous surgery, are very critical to the success of PDR surgical treatment. The study will explain the surgical opportunity of proliferative diabetic retinopathy and analyze the clinical characteristics of statistical data. The research is described below.

2. Research Methods

In this study, 66 PDR patients (89 eyes) were admitted to our hospital from January 2020 to January 2023, including 34 males (44 eyes), 32 females (45 eyes), 55-75 years old. All patients signed an informed consent form, and this study was approved by the Ethics Committee of our hospital.

Included criteria: (1) diabetes complications lead to retinopathy; (2) vision loss; (3) ineffective drug treatment. Exclusion criteria: (1) Poor systemic basic conditions; poor cardiopulmonary function. (2) Total loss of vision.

Efficacy evaluation criteria; postoperative vision is the final vision during the follow-up period. A vision improvement of 2 or more lines is an improvement in vision. A loss of two or more lines of vision is a loss of vision. Those who maintain or improve vision after treatment are effective for treatment. Surgical complications; including intraoperative Chinese medicine-derived hiatus; postoperative bleeding (it is pointed out that the blood time exceeds 1 month after the operation), omen detachment, neovascular glaucoma, etc. Observation indicators: Observe the best correction of vision before and after surgery 3m, 6m, 12m after surgery, and the occurrence of postoperative complications. Statistical method The research data is processed by SPSS statistical software. The counting data is expressed in frequency and percentage, and the difference of $P < 0.05$ is statistically significant.

3. Results

According to the clinical manifestations, disease characteristics and intraoperative conditions of patients, 15 cases of retinal photocoagulation were used, 17 cases of gas-liquid exchange or heavy water injection, and 37 cases of C3F8 gas or silicone oil were used to be well reset the retina. See Figure 1.

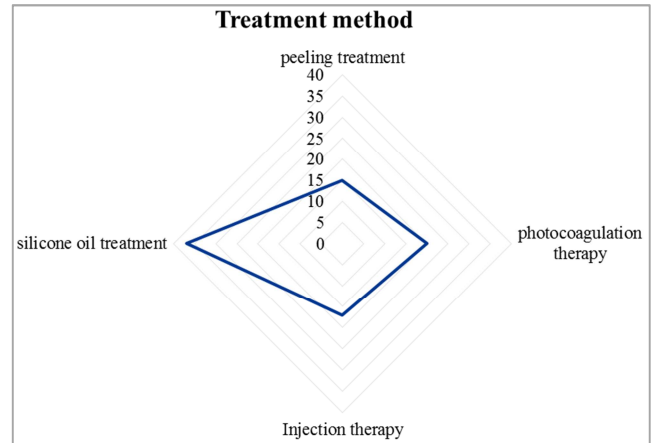


Figure 1. Treatment method.

Results In March of postoperative follow-up, the postoperative corrected vision improved 20 eyes, the vision did not improve or lower 2 eyes, and 1 eye was lost. Results In June of postoperative follow-up, the postoperative corrected vision improved 23 eyes, 5 eyes of vision did not improve or decreased, and 5 eyes were lost. Results In December of the postoperative follow-up, the postoperative corrected vision improved 25 eyes, the vision did not improve or decreased by 5 eyes, and 3 eyes were lost. See Figure 2.

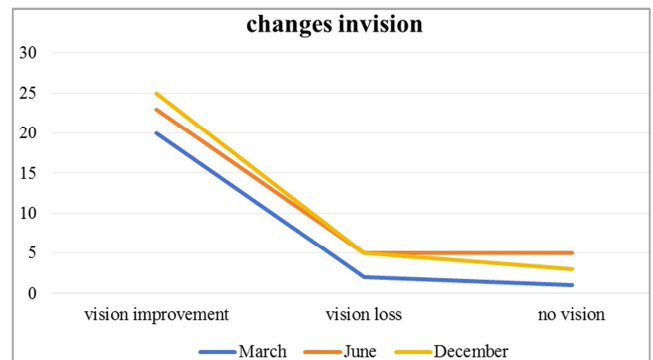


Figure 2. Changes invision.

Stage IV-V vision improves 45 eyes, and Stage VI vision improves 12 eyes. A total of 37 eyes were filled with silicone oil, 25 eyes were improved in phase IV-V, and 12 eyes were improved in stage VI. See Table 1.

Table 1. The patient stage table.

By stages	age / years	caseload	Vision improvement	Silicone oil therapy	amaurosis	hemorrhage
IV	55.0 ~70.0	34.0	21.0	13	1	1
V	56.0 ~69.0	31.0	23.0	12	2	0
VI	58.0 ~75.0	24.0	12.0	12	0	0
t	-0.423	-0.568	-0.395	0.245	0.133	0.210
P	0.638	0.504	0.710	0.844	0.730	0.808

4. Discussion

In this study, the proportion of vision improvement after vitrectomy in patients with stage IV and V PDR of diabetic

retinopathy was 65/89(73.033)% , of which 26/65(40)% had postoperative vision >0.1 . The postoperative vision improvement of PDR VI patients is 50%, and the vision of no patient is more than 0.1. After the operation, there was blackness in three eyes, and bleeding in one eye after the operation.

The results of this study show that there is a significant difference between early PDR vitreous surgery and advanced PDR surgery, and there is a significant difference in the recovery of vision after surgery ($P < 0.05$). Because early surgical retinal separation is easier and has fewer complications, it can also terminate the process of PDR through all laser treatment of the affected eye [3-4].

Stage VI patients with diabetic retinopathy in the study were given 50% of patients after vitrectomy; their postoperative vision was still low. This result is similar to other literature reports at home and abroad [5-7]. If such a patient does not choose surgical treatment, the patient's affected eyes will eventually be blind. Therefore, it is still of great significance for patients with PDR VI to perform vitreous surgery in a timely manner. During the study, it is necessary to fully understand the general situation of the patient's whole body, cardiopulmonary function, and strictly check the vision, visual function, visual electrophysiology and other conditions. Actively arrange surgical treatment.

There were no V-stage PDR patients with vitreous hemorrhage in the study. Some researchers suggest vitrectomy when patients with diabetic retinopathy have serious complications such as vitreous hemorrhage or traction retinal detachment [8-9].

In the study, patients with stage V diabetic retinopathy without vitreous hemorrhage were randomly divided into two groups for PRP treatment (15 eyes) and vitrectomy surgery (16 eyes). The PRP treatment group had an effective rate of 9/15 (60.0%), 3 eyes (20%) were visually reduced, and 4 eyes (26.7%) had ineffective vitrectomy after one or more additional photocoagulation. In the vitreous surgical treatment group; 14/16 (87.5%) were visually improved after surgery. It can be seen that vitreous surgery is treated under the premise of perfect equipment and the improvement of the surgeon's surgical skills; vitreous surgery is performed for patients with V-stage diabetic retinopathy without vitreous hemorrhage; such patients have better postoperative vision than the conventional PRP treatment group, that is, early vitreous surgery, and the prognosis of patients is better [10-12]. The results can also show that 17 patients with stage IV of diabetic retinopathy were treated with PRP and 17 patients underwent vitrectomy. The post-treatment efficiency of PRP in this group was 12/17 (70.6%). 16 patients with stage V diabetic retinopathy were treated with PRP and 15 patients with vitrectomy. The effective rate of PRP treatment in this group of studies was 10/16 (62.5%), which was significantly lower than that of the former. After 3 months of re-examination of FFA and PDR IV, 20 neovascular blood vessels (58.9%) were not faded and added to photocoagulation. Among them, 3 cases (15.0%) had vitreous incision due to vitreous bleeding. Exception; In V-stage PDR patients, there were 15 eyes (48.4%) of neovasculars that did not fade and add photocoagulation. One case (3.22%) underwent vitrectomy after one or more additional photocoagulation. The research results show that it is also very important to choose the treatment timing of PRP reasonably. Patients with early retinal photocoagulation have a lower incidence of vitreous surgery

for vision loss or vitreous bleeding [13-16]. The most common complication in vitreous surgery is iatrogenic hiatus [17]. The study found that its incidence was significantly higher than that of patients with stage V and stage VI PDR. The main reason is that the occurrence of iatrogenic pores is related to the degree of hyperplasia of the endometima [17]. Vitreous rebleeding is the most common postoperative complication of vitreous surgery [18]. Most patients with postoperative vitreous hemorrhage is related to insufficient intraoperative laser amount or insufficient range, and partly related to anterior fibrovascular hyperplasia [19]. Some scholars believe that when the affected eye is actively treated by active surgery in the early stage of PDR, because the affected eye is active in the active stage of neovascular hyperplasia, it will increase complications such as vitreous hemorrhage and neonatal blood glaucoma [20]. Serious complications such as black haze and retinal detachment also appeared in patients with stage VI of diabetic retinopathy. The summary shows that vitrectomy is positive, safe and suitable for patients with diabetic retinopathy, because such treatment can effectively improve the visual function of patients with diabetic retinopathy. The results of the study confirmed that the vision improvement of postoperative patients in stage IV-V was significantly better than that of patients with stage VI. Finally, a strict grasp of surgical opportunities and indications is the key to the success of surgical treatment.

5. Conclusion

For patients with diabetic retinopathy, active, safe and appropriate choice of vitrectomy can effectively improve the visual function of diabetic retinopathy patients. In the results of this study, it was confirmed that the visual acuity improvement of patients in stage IV to V after surgery was significantly better than that in stage VI. The clinician should strictly grasp the opportunity of surgery and the indications of surgery as the ladder of successful surgical treatment.

Author's Statement

This study is approved by the author, and its case data is used for academic research. The research data is provided by wang tao; all authors have no conflicts of interest. Wang tao: Write a paper. Liu Chao: Statistics, review essays and paper drawing.

References

- [1] Zhang Chengfen, Zhang Huirong, etc. Eye complications and treatment of diabetes [J]. Beijing: People's Health Publishing House 2023.62.
- [2] Cunba-vaz J. Lowering the risk of visual impairment and blindness [J]. Diabet Med? 2020 15 (Suppl4): 47.
- [3] Diabetic Retinopathy Vitrectomy Study Research Group. Early vitrectomy for severe proliferative diabetic retinopathy in eyes with useful vision. Results of a randomized trial: Diabetic Retinopathy Vitrectomy Study Report 3 [J]. Ophthalmology 2022. 95: 107.

- [4] Diabetic Retinopathy Vitrectomy Study Research Group: Early vitrectomy for severe vitreous hemorrhage in diabetic retinopathy Diabetic Retinopathy Vitrectomy Study Report [J]. Ophthalmol 2021. 108: 958.
- [5] Grewing, RMester U. Early vitrectomy for progressive diabetic proliferations covering the macular [J] BrJOphtal Mol? 2022. 78: 433.
- [6] Ferris F. Early photocoagulation in patients with either type I or type II diabetes [J]. Trans Am Ophthalmol Soc 2023 94: 505.
- [7] Wu Fan, Zhu Xiaobo, He Yongning. The timing of vitrectomy in patients with proliferative diabetic retinopathy and its effect on vision improvement [J]. Journal of Baotou Medical College, 2019, 35 (09): 51-52.
- [8] Li Chunyan, Zhu Antai. Choosing the timing of diabetic retinopathy complicated with vitreous volume blood surgery [J]. Journal of Xinxiang Medical College, 2021, 35 (08): 731-734.
- [9] Zhang Hongying. Retrospective analysis of the prognosis of visual function of stage V and stage VI diabetic retinopathy [D]. Guangzhou University of Traditional Chinese Medicine, 2019.
- [10] Zhang Qi, Feng Jie, Cheng Xukang, etc. Timing of cataract surgery for severe non-proliferative diabetic retinopathy [J]. International Journal of Ophthalmology, 2023, 13 (01): 92-93.
- [11] Biography of the Prince. Analysis of the surgical timing and clinical efficacy of vitrectomy for diabetic vitreous blood [D]. Dalian Medical University, 2019.
- [12] Ji Huiqian, Li Lingli, Liang Min, etc. Discussion on the timing of intervention and treatment of vitreous surgery for diabetic retinopathy [J]. Journal of Clinical Ophthalmology, 2019, 18 (01): 20-22.
- [13] Xu Jingmei, Chen Huiru, Xu Bing, etc. Discussion on the surgical timing and curative effect of diabetic retinopathy [J]. Journal of Occupational Eye Diseases for Eye Trauma. Eye surgery, 2020 (04): 266-268.
- [14] Ji Huiqian, Liang Min, Li Lingli, etc. Evaluation of the application of intraocular electrocoagulation in vitreous surgery for proliferative diabetic retinopathy [J]. Journal of Clinical Ophthalmology, 2023, 21 (04): 38-39.
- [15] Chen Nan, Teng Yan, Liu Fei, etc. Observation and analysis of the surgical effect of retinopathy in proliferative diabetics [J]. Medicine and Philosophy (B), 2023, 34 (03): 30-32.
- [16] Long Ting, Chen Jia, Du Lei, etc. Advances in surgical treatment of proliferative diabetic retinopathy [J]. International Journal of Ophthalmology, 2017, 17 (11): 2069-2072.
- [17] Liu Sanmei, Li Jie, Dong Wentao, etc. Medium- and long-term clinical observation of intravitreal injection of Compasipp and retinal photocoagulation in the treatment of proliferative diabetic retinopathy [J]. Journal of Chengdu University of Traditional Chinese Medicine, 2020, 40 (01): 63-65.
- [18] Ke Yi, Zhang Yuan, Wang Xiuqin, etc. Comprehensive Study on the Efficacy of Conservative Treatment and Surgical Treatment of Glass Volume Blood [J]. Chinese practical medicine, 2020, 15 (16): 20-22.
- [19] Jiang Shengqun. Effects of different timings of leizhumonumab on the effect of vitreous excision for hyperplasia of diabetic retinopathy [J]. Journal of Mudanjiang Medical College, 2019, 40 (04): 78-80. DOI: 10.13799/j.cnki.mdjyxyxb.2019.04.026.
- [20] Tan Zhouli, Fan Wei. Postoperative complications and timing of diabetic cataracts [J]. Huaxi Medicine, 2019, 32 (04): 612-617.