

# Comparative Analysis of the Clinical Efficacy Characteristics of Full Femtosecond Smile Correction and FS-LASIK Refractive Correction - A Population-Based Study

Wang Tao<sup>1,\*</sup>, Liu Chao<sup>2</sup>

<sup>1</sup>Department of Ophthalmology, Ding Zhou Tian Shun Eye Hospital, Baoding, China

<sup>2</sup>Department of Surgery, Clinical Medicine, University Prima Indonesia, Medan, Indonesia

## Email address:

wangtaok2023@163.com (Wang Tao), 13183290311@163.com (Wang Tao), liuchao1838044@163.com (Liu Chao)

\*Corresponding author

## To cite this article:

Wang Tao, Liu Chao. Comparative Analysis of the Clinical Efficacy Characteristics of Full Femtosecond Smile Correction and FS-LASIK Refractive Correction - A Population-Based Study. *International Journal of Ophthalmology & Visual Science*. Vol. 8, No. 3, 2023, pp. 44-47. doi: 10.11648/j.ijovs.20230803.12

Received: October 13, 2023; Accepted: October 27, 2023; Published: November 9, 2023

**Abstract:** Background: The widespread use of full femtosecond laser technology in the field of refractive errors has pushed corneal refractive surgery in a non-invasive direction. Common methods include femtosecond laser-assisted excimer laser in situ corneal grinding (FS-LASIK) and femtosecond laser small incision corneal matrix lens extraction (SMILE). What are the clinical characteristics of the two after surgery and the differences in the clinical manifestations after the operation. This study will explain the advantages and disadvantages and research results of the two types of surgery. Research methods; From January 2021 to January 2023, 25 refractive irregularities (49 eyes) and 12 male patients who were corrected by FS-LASIK in the hospital; 13 cases of women were selected as the FS-LASIK group. In addition, 30 refractive irregularities (60 eyes) and 17 male patients who came to the hospital for SMILE correction at the same period were selected as the SMILE group. In the study, it is necessary to count UDVA, SE, HOAs, bulbar, comet difference, tear secretion test, TBUT, OSDI score, BCDVA, astigmatism, etc. at different time stages of preoperative and postoperative 1w, 1m, 1m, 3m and 6m before and 6m. Statistical analysis and clinical characteristics are carried out through the above data. Objective; Compare the clinical characteristics, advantages and disadvantages of femtosecond laser small incision corneal matrix lens extraction (SMILE) and femtosecond laser-assisted excimer laser in situ corneal grinding (FS-LASIK) in the treatment of refractive errors. Results; Compared with the two groups of patients, the differences in postoperative UDVA, SE, HOAs, spherical aberration, comet difference, tear secretion test, TBUT and OSDI scores were statistically significant ( $P < 0.05$ ), but the differences between BCDVA and astigmatism were not statistically significant ( $P > 0.05$ ). The HOAs of SMILE group patients (30) were lower than those in the FS-LASIK group ( $P < 0.05$ ). The coma difference between 1 week and January to June after surgery in the SMILE group was higher than that in the FS-LASIK group ( $P < 0.05$ ). The TBUT of patients in the SMILE group was significantly longer than that of the FS-LASIK group ( $P < 0.05$ ).

**Keywords:** Corat Corneal Fitting Surgery, Femtosecond Laser-Assisted Excimer Laser, Myopia, Smile Surgery, Fs-Lasik, Surgery

## 1. Introduction

The widespread use of full femtosecond laser technology in the field of refractive errors has pushed corneal refractive surgery in a non-invasive direction. What are the clinical characteristics of the two after surgery and the differences in the clinical manifestations after the operation. This study will

explain the advantages and disadvantages and research results of the two types of surgery. At present, there are more literature to confirm the effectiveness and safety of FS-LASIK and SMILE in correcting myopia and astigmatism [1]. In the comparison of the two operations, SMILE surgery shows certain advantages [2-3]. In addition, there are also documents confirming that the steeper the cornea in patients with high

myopia, the brighter the overcorrection [4], suggesting that the postoperative refractive state may be related to preoperative refractive index [5]. On the basis of the preliminary results, this study further studied, obtained the clinical data of June after the operation, and finally analyzed the clinical characteristics of the statistical data. The study is described below.

## 2. Research Methods

In this study, 25 refractive irregularities (49 eyes) and 12 male patients who were corrected by FS-LASIK correction in our hospital from January 2021 to January 2023; 13 females, aged 18-30 years old, with an average age of 25 years old, as the FS-LASIK group. In addition, 30 refractive irregularities (60 eyes) and 17 males who had been corrected in the hospital during the same period; and 13 females, aged 18-33 years old, with an average age of 26, were selected as the SMILE group. All patients signed an informed consent form, and this study was approved by the Ethics Committee of our hospital. Inclusion criteria: age 18 to 35 years old; central corneal thickness (CCT)  $\geq 500$   $\mu\text{m}$ ; expected remaining corneal matrix bed thickness  $\geq 280$   $\mu\text{m}$ ; refractive index change within  $\pm 0.50$  D in the past 1 year; optimal corrected telemetry (BCDVA) is 20/20 and above; spherical microscope is  $-6.0 \sim -10.0$  D and columnar microscope is  $-3.5 \sim 0$  D; the follow-up period, and the data is complete. Exclusion criteria: poor systemic basic condition; poor cardiopulmonary function. Eye infection and inflammatory

reaction. Severe dry eyes and systemic connective tissue diseases. SLE. Cataract. Glaucoma that has not been controlled. Serious fundus diseases and other serious eye diseases other than refractive errors such as corneal spots. People with mental illness. Efficacy evaluation and observation criteria; UDVA, SE, HOAs, spherical aberration, comet difference, tear secretion test, TBUT, OSDI score, BCDVA, astigmatism need to be counted at different time stages before, postoperative, 1w, 1m, 3m and 6m. Statistical method: The research data is processed with SPSS statistical software. The counting data is expressed in frequency and percentage. The difference of  $P < 0.05$  is statistically significant.

## 3. Results

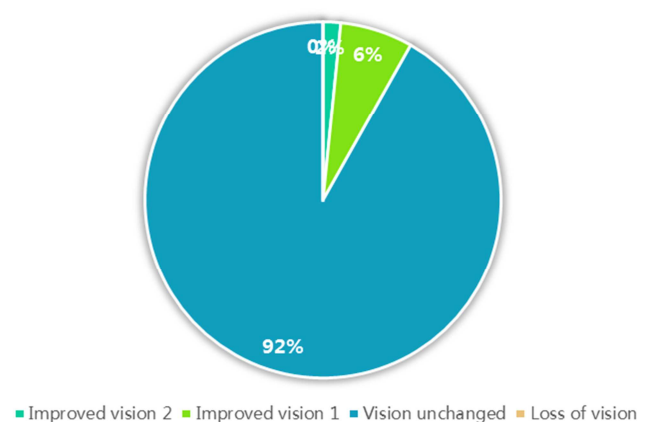
All admitted patients successfully completed the operation and could be re-examined on time. There were no serious complications after the operation. The general preoperative data of the two groups of patients are shown in Table 1. There are 25 patients (49 eyes) and 12 males in the FS-LASIK group; 13 females, aged 18-30 years old, with an average age of 25, 30 (60 eyes) and 17 male patients in the SMILE group; 13 females, aged 18-33 years old, with an average age of 26. The independent sample T test results showed that the differences in preoperative age, SE, spherical microscopy, columnar microscopy, CCT and BCDVA of the two groups of patients were not statistically significant (both  $P > 0.05$ ).

**Table 1.** Comparison of general preoperative data of patients in the SMILE and FS-LASIK groups.

Organize	Age/years	SE/D	spherical mirror/D	cylindrical mirror/D	CCT/ $\mu\text{m}$	BCDVA (log MAR)
SMILE	26.0 $\pm$ 8.0 (18 ~33)	-8.19 $\pm$ 1.28	-7.65 $\pm$ 1.13	-0.78 $\pm$ 0.79	545.28 $\pm$ 28.80	-0.08 $\pm$ 0.16
FS-LASIK	25.0 $\pm$ 6.8 (18 ~30)	-8.08 $\pm$ 1.05	-7.56 $\pm$ 1.26	-0.73 $\pm$ 0.90	545.45 $\pm$ 27.60	-0.07 $\pm$ 0.16
t	-0.523	-0.668	-0.595	0.133	0.110	-1.185
P	0.538	0.400	0.510	0.830	0.908	0.198

IN THE SMILE GROUP (30 CASES), THE SE WAS LOWER THAN THAT OF THE FS-LASIK GROUP, AND THE SE IN THE JANUARY-June POSToperative WAS HIGHER THAN THAT IN THE FS-LASIK GROUP ( $P < 0.05$ ). The HOAs of patients in the SMILE group (30 cases) was lower than that of the FS-LASIK group ( $P < 0.05$ ), and the absolute value of the ball difference was significantly lower than that of the FS-LASIK group ( $P < 0.05$ ). The coma difference between 1 week and January to June after surgery in the SMILE group was higher than that in the FS-LASIK group ( $P < 0.05$ ). The TBUT of patients in the SMILE group was significantly longer than that of the FS-LASIK group ( $P < 0.05$ ). THE SIGHT OF THE SMILE GROUP INCREASED BY 2 ROWS WITH 1 EYE (1.6%), 4 EYES (6.6%) FOR 1 ROW, AND 55 EYES (91.8%) WITH VISUALLY CHANGED, See Figure 1.

**SMILE : postoperative visual acuity**

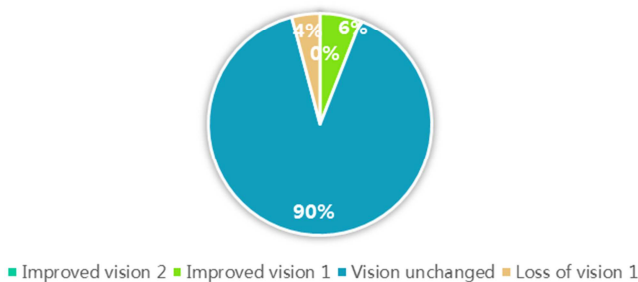


**Figure 1.** SMILE: Postoperative visual acuity.

FS-LASIK group patients improved their vision by 3 eyes (6.1%), 44 eyes (89.7%) with unchanged vision, and 2 eyes (4.2%) for 1 row of vision loss. See Figure 2. Neither group of

patients saw 2 rows of vision loss of 2 or more.

#### FS-LASIK : postoperative visual acuity



**Figure 2.** FS-LASIK: postoperative visual acuity.

## 4. Discussion

FS-LASIK surgery is a safe and effective method to treat myopia and astigmatism. In FS-LASIK, the manufacturing process of corneal flap will cause complications such as dry eye symptoms, and will also lead to halo and glare after surgery [5]. Therefore, there is a SMILE surgical method that does not require the preparation of corneal flaps [6-8]. Studies have shown that the differences between UDVA, BCDVA and SE after FS-LASIK and SMILE are not statistically significant ( $P > 0.05$ ), and both have achieved good therapeutic results, which is consistent with the results of this study [9-10]. In the study, the astigmatism difference between the two groups of patients in preoperative and postoperative June was not statistically significant (both  $P > 0.05$ ), which also confirmed the conclusion of some scholars' conclusion that astigmatism was undercorrected after corneal refractive surgery [11-14]. The results of this study found that patients in the two surgical groups increased HOAs, spherical aberration and coma after surgery. SMILE was mainly manifested in the increase in coma, while the introduction of HOAs and spherical aberration were less, which is consistent with the research conclusions of some scholars [15-18]. The SMILE surgical group is as safe and effective as the FS-LASIK surgical group in correcting high myopic astigmatism, but in terms of long-term efficacy, SMILE is more stable than FS-LASIK, and there is less postoperative refractive regression [19-20]. In terms of aberrations, SMILE introduces fewer HOAs and spherical aberrations, but more comas [21]. In terms of dry eye, the symptoms of dry eye after SMILE surgery are mild, the recovery is faster, and the patient's satisfaction is high [22-25]. This study has certain limitations, non-random research, what kind of surgery the patient wants to perform, so there is a certain bias in the results. It is hoped that more scholars will conduct stricter randomized clinical trials; select appropriate criteria and quantities to study, and evaluate the analysis of clinical effects after SMILE surgery and FS LASIK surgery, which is of positive significance for future clinical work.

## 5. Conclusion

Conclusion SMILE is as safe and effective as FSLASIK surgery. In clinical practice, SMILE has a decisive advantage in long-term stability. SMILE introduces HOAs with less spherical difference and more coma. Patients who choose SMILE surgery have a short duration of dry eye after surgery, and their condition recovers faster.

## Author's Statement

This study is approved by the author, and its case data is used for academic research. The research data is provided by wangtao; all authors have no conflicts of interest. Wang tao: Write a paper. Liu Chao: Statistics, review essays and paper drawing.

## References

- [1] Ma Jing, XIA Li-Kun, LIU Henan. Comparison of the efficacy of SMILE and FS-LASIK in the treatment of patients with high myopia astigmatism [J]. New Advances in Ophthalmology, 2019, 43 (2) : 116-121.
- [2] IVARSEN A, ASP S, HJORTDAL J. Safety and complications of more than 1500 small-incision lenticule extraction procedures[J]. Ophthalmology, 2020, 121(4): 822-828.
- [3] HAN T, XU Y, HAN X, ZENG L, SHANG J, CHEN X, et al. Three-year outcomes of small incision lenticule extraction (SMILE) and femtosecond laser-assisted laser in situ keratomileusis (FS-LASIK) for myopia and myopic astigmatism [J]. Br J Ophthalmol, 2021, 103(4): 565-568.
- [4] DE BENITO-LLOPIS L, TEUS MA, SANCHEZ-PINA J M, GILCAZORLA R. Influence of preope rative keratometry on refractive results after laser-assisted subepithelial keratectomy to correct myopia [J]. J Cataract Refract Surg, 2018, 34(6): 968-973.
- [5] XIA L K, MA J, LIU H N, SHI C, HUANG Q. Three-year results of small incision lenticule extraction and wavefront-guided femtosecond laser-assisted laser in situ keratomileusis for correction of high myopia and myopic astigmatism [J]. Int J Ophthalmol, 2020, 11(3): 470-477.
- [6] KAMIYA K, SHIMIZU K, IGARASHI A, KOBASHI H, KOMATSU M. Comparison of visual acuity, higher-order aberrations and corneal asphericity after refractive lenticule extraction and wavefront-guided laser-assisted in situ keratomileusis for myopia [J]. Br J Ophthalmol, 2013, 97(8): 968-975.
- [7] SHAH R, SHAH S, SENGUPTA S. Results of small incision lenticule extraction: all-in-one femtosecond laser refractive surgery [J]. J Cataract Refract Surg, 2019, 37(1): 127-137.
- [8] TANERI S, KIESSLER S, ROST A, SCHULTZ T, DICK H B. Small incision lenticule extraction for the correction of high myopia [J]. Eur J Ophthalmol, 2020, 30(5): 917-927.
- [9] RANDLEMAN J B, DAWSON D G, GROSSNIKLAUS H E, MCCAREY B E, EDELHAUSER H F. Depth-dependent cohesive tensile strength in human donor corneas: implications for refractive surgery [J]. J Refract Surg, 2018, 24(1): S85-S89.

- [10] IVARSEN A, HJORTDAL J. Correction of myopic astigmatism with small incision lenticule extraction [J]. *J Refract Surg*, 2022, 30(4): 240-247.
- [11] ZHANG J, WANG Y, CHEN X. Comparison of moderate-to-high-astigmatism corrections using wavefront-guided laser in situ keratomileusis and small-incision lenticule extraction [J]. *Cornea*, 2023, 35(4): 523-530.
- [12] PEDERSEN I B, IVARSEN A, HJORTDAL J. Changes in astigmatism, densitometry, and aberrations after smile for low to high myopic astigmatism: a 12-month prospective study [J]. *J Refract Surg*, 2023, 33(1): 11-17.
- [13] CHAN T C, NG A L, CHENG G P, WANG Z, YE C, WOO VCP, et al. Vector analysis of astigmatic correction after small-incision lenticule extraction and femtosecond-assisted LASIK for low to moderate myopic astigmatism [J]. *Br J ophthalmol*, 2019, 100(4): 553-559.
- [14] JUN I, KANG D S Y, REINSTEIN D Z, ARBA-MOSQUERA S, ARCHER T J, SEO K Y, et al. Clinical outcomes of SMILE with a triple centration technique and corneal wavefrontguided transepithelial PRK in high astigmatism [J]. *J Refract Surg*, 2021, 34(3): 156-163.
- [15] ALIÓDEL BARRIO J L, VARGAS V, AL-SHYMALI O, ALIÓJ L. Small incision lenticule extraction (SMILE) in the correction of myopic astigmatism: outcomes and limitations-an update [J]. *Eye Vis (Lond)*, 2022, 4: 26.
- [16] SEKUNDO W, GERTNERE J, BERTELMANN T, SOLOMATIN I. One-year refractive results, contrast sensitivity, highorder aberrations and complications after myopic small-incision lenticule extraction (ReLEx SMILE)[J]. *Graefes Arch Clin Exp Ophthalmol*, 2023, 252(5): 837-843.
- [17] LIN F, XU Y, YANG Y. Comparison of the visual results after SMILE and femtosecond laser-assisted LASIK for myopia [J]. *J Refract Surg*, 2022, 30(4): 248-254.
- [18] GANESH S, GUPTA R. Comparison of visual and refractive outcomes following femtosecond laser-assisted LASIK with SMILE in patients with myopia or myopic astigmatism [J]. *J Refract Surg*, 2023, 30(9): 590-596.
- [19] FANG L, WANG Y, HE X. Theoretical analysis of wavefront aberration caused by treatment decentration and transition zone after custom myopic laser refractive surgery [J]. *J Cataract Refract Surg*, 2022, 39(9): 1336-1347.
- [20] SUN C C, CHANG C K, MA D H, LIN Y F, CHEN K J, SUN M H, et al. Dry eye after LASIK with a femtosecond laser or a mechanical microkeratome [J]. *Optom Vis Sci*, 2019, 90 (10): 1048-1056.
- [21] DONNENFELD E D, EHRENHAUS M, SOLOMON RMAZUREK J, ROZELL J C, PERRY H D. Effect of hinge width on corneal sensation and dry eye after laser in situ keratomileusis [J]. *Cataract Refract Surg*, 2018, 30(4): 790-797.
- [22] WANG D, LIU M, CHEN Y, ZHANG X Y, XU Y T, WANG J C, et al. Differences in the corneal biomechanical changes after SMILE and LASIK [J]. *J Refract Surg*, 2023, 30 (10): 702-707.
- [23] XU Y, YANG Y. Dry eye after small incision lenticule extraction and LASIK for myopia [J]. *J Refract Surg*, 2022, 30(3): 186-190.
- [24] J M B, Arne O, Pablo D S, et al. Prediction of refractive error and its progression: a machine learning-based algorithm. [J]. *BMJ open ophthalmology*, 2023, 8(1).
- [25] Pierce G. Creating a positive patient financial journey for refractive error procedures [J]. *Ophthalmology Times*, 2023, 48(9).