

# Perfusion Findings in Surgically Resolved Myopic Foveoretinal Detachment

Miguel Angel Quiroz-Reyes<sup>1,\*</sup>, Erick Andres Quiroz-Gonzalez<sup>2</sup>, Jorge Morales-Navarro<sup>2</sup>, Boris Moreno-Andrade<sup>1</sup>, Alejandra Nieto-Jordan<sup>1</sup>, Federico Graue-Wiechers<sup>1</sup>

<sup>1</sup>Retina Service, Institute of Ophthalmology, National Autonomous University of Mexico, Mexico City, Mexico

<sup>2</sup>Department of Ophthalmology, Institute of Ophthalmology, National Autonomous University of Mexico, Mexico City, Mexico

## Email address:

[drquiroz@prodigy.net.mx](mailto:drquiroz@prodigy.net.mx) (M. A. Quiroz-Reyes)

\*Corresponding author

## To cite this article:

Miguel Angel Quiroz-Reyes, Erick Andres Quiroz-Gonzalez, Jorge Morales-Navarro, Boris Moreno-Andrade, Alejandra Nieto-Jordan, Federico Graue-Wiechers. Perfusion Findings in Surgically Resolved Myopic Foveoretinal Detachment. *International Journal of Ophthalmology & Visual Science*. Vol. 6, No. 4, 2021, pp. 252-262. doi: 10.11648/j.ijovs.20210604.21

**Received:** November 16, 2021; **Accepted:** December 3, 2021; **Published:** December 10, 2021

---

**Abstract:** *Purpose:* Published data on long-term macular perfusional findings and qualitative vessel density (VD) evaluation of myopic foveoretinal detachment (FRD) are limited. This study aimed to evaluate the OCT angiographic findings after uncomplicated successful macular surgery in fully surgically resolved myopic FRD. *Methods:* Between October 2016 and April 2020, an interventional, single-surgeon case series was conducted involving three structurally fully resolved highly myopic eyes with FRD. Long-term postoperative spectral domain-optical coherence tomography (SD-OCT) and functional and follow-up perfusion evaluations with SD-OCT and OCT angiography were performed. The main outcome was long-term structural and macular perfusion status after successful surgical resolution of myopic FRD. *Results:* The mean evolution time of myopic FRD was  $7.33 \pm 3.68$  months. The mean follow-up time was  $59.3 \pm 12.20$  months and the mean time for resolution of myopic FRD was  $4.6 \pm 1.98$  weeks. Using a paired-samples permutation test, we observed that surgery was associated with a significant improvement in visual acuity: best-corrected visual acuity decreased from  $\log\text{MAR } 0.88 \pm 0.15$  pre-surgery to  $0.36 \pm 0.20$  post-surgery ( $P < 0.0001$ ). Qualitative VD evaluation patterns were lower in eyes post-surgery than in normal emmetropic and highly myopic eyes. The observed foveal avascular zone (FAZ) area was large and irregular in fully resolved myopic FRD. A lack of SD-OCT structural postoperative findings and better qualitative perfusion findings were associated with better final visual results. *Conclusion:* The results revealed postoperative microstructural abnormalities on SD-OCT with VD qualitative deficiencies in the superficial vascular complex of the macula with FAZ abnormalities in the three eyes.

**Keywords:** Deep Vascular Plexus, Foveoretinal Detachment, High Myopia, Myopic Foveoschisis, Foveal Avascular Zone, Perfusion Macular Status, Vessel Density, Superficial Vascular Plexus

---

## 1. Introduction

In industrialized countries, myopia is widely recognized as a tremendous public health challenge, causing significant visual loss and serving as a risk factor for a range of other serious ocular conditions [1]. In the United States, myopia affects ~2% of the general population aged 12 to 54 years [2]. Pathological myopia is the fifth-leading cause of low vision or blindness in Japan and is the second leading cause among individuals > 40 years in China [3].

Pathological myopia (PM) is defined as excessive axial

elongation associated with structural changes in the posterior segment of the eye, including posterior staphyloma, myopic maculopathy, and high myopia-associated optic neuropathy, which can lead to loss of best-corrected visual acuity (BCVA) [4].

Myopic macular degeneration is a vision-threatening condition that is generally associated with high myopia comprising diffuse or patchy macular atrophy with or without lacquer cracks, macular Bruch's membrane defects,

chorionovascular proliferation, and myopic traction maculopathy (MTM) according to the recent amyloid/tau/neurodegeneration (ATN) classification [5] and a meta-analysis for PM—an international photographic classification and grading system for myopic maculopathy [6].

High myopia is defined as a refractive error with a spherical equivalent  $> -6.0$  diopters or an axial length  $> 26.5$  mm. Pathological macular changes in eyes with high myopia are characterized by retinal atrophy, ruptures of Bruch's membrane, posterior staphyloma (PS), scleral stretching, internal limiting membrane (ILM) incompliance, and sclerotic thinning [4, 7, 8].

Highly myopic eyes with foveal or macular myopic foveoschisis (MF) and myopic foveoretinal detachment (FRD) naturally progress to produce a partial- or full-thickness myopic macular hole (MH) and myopic macular hole retinal detachment (MHRD) in advanced stages of this condition [9, 10]. MF was first identified by Takano and Kishi based on optical coherence tomography (OCT) and B-scan views and was identified in 34% of highly myopic eyes with PS [11-13]. MF and FRD are considered as the early stages of MTM that could remain stable over a long period, then slowly progress to more advanced and severe forms of myopic FRD, and finally evolve to partial- or full-thickness MH with or without MHRD [14-18].

Recently, perfusion evaluation and qualitative and quantitative evaluation of vessel density (VD) at the macula level have gained popularity as novel strategies for the evaluation and management of different macular pathologies [19-21]. However, published data on long-term macular perfusion findings and qualitative VD evaluation of FRD are limited.

To perform a qualitative assessment of macular microcirculation in fully surgically resolved highly myopic eyes, we evaluated the OCT angiographic findings in three highly myopic eyes with long-term fully resolved FRD after uncomplicated successful macular surgery. For this study, we selected three surgical cases that fulfilled strict criteria designed to minimize possible confounding variables: one normal emmetropic and one healthy highly myopic eye were used as controls.

## 2. Patients and Methods

### 2.1. Study Design and Patient Selection

The retina service at the *Institute of Ophthalmology Hospital, "Conde de Valenciana" Foundation* in Mexico City provided authorization and released the patients' electronic clinical records to generate the database used in this retrospective study. The study was approved by the institutional review board (no approval or reference number was provided for retrospective studies by this institution in Mexico City). Written informed consent was obtained from all patients according to the institutional guidelines. Data are available from the Imagenology and Psychophysics Laboratory at the retina department of the institution.

Two groups of eyes, namely the control group and study group, were selected and retrospectively analyzed at the Retina Service of the Institute of Ophthalmology from October 2016 to April 2020.

The surgical study group comprised three eyes of three consecutive patients who fulfilled the diagnosis of symptomatic myopic FRD and who had undergone vitrectomy with successful and uncomplicated macular surgery using the fovea sparing ILM removal surgical technique. Three-port pars plana vitrectomy was performed in these symptomatic and highly myopic eyes with evidence of a progressive decrease in BCVA. All the selected eyes possessed an axial length  $> 26.5$  mm, with no evidence of patchy foveal-affected chorioretinal atrophy, diffuse macular chorioretinal atrophy, or quiescent or active myopic choroidal neovascularization according to the ATN classification [5].

The control group comprised one normal emmetropic eye and one healthy, highly myopic eye.

In the study group, the diagnosis of myopic FRD traction maculopathy was confirmed using spectral-domain (SD)-OCT findings consistent with internal or external schisis-like foveomacular thickening, presence or absence of epiretinal membranes (ERMs), residual hyaloidal cortical remnants, central submacular presence of subretinal fluid, and no evidence of partial- or full-thickness MH on SD-OCT examination.

The emmetropic control eye and the healthy highly myopic eye were recruited from individuals without a previous disease history and with BCVA  $\geq 20/20$ , intraocular pressure  $\geq 10$  mmHg and  $\leq 21$  mmHg, without any abnormalities found on dilated fundus examination, SD-OCT B, and crossline scanning examination.

Individuals were matched for age, sex, study period, and follow-up period. None of the eyes included in the study received adjunctive therapy such as intravitreal injection or laser photocoagulation during the study period.

Only patients with a follow-up period of at least 6 months were statistically analyzed. All eyes were followed up at the participating institution in a standardized fashion every month for more than 6 months and examined every 6 months thereafter until the final follow-up visit. The follow-up durations ranged from 24 to 65 (mean:  $59.3 \pm 12.10$ ) months.

### 2.2. Examinations

All patients underwent general ophthalmic evaluations and preoperative examinations, including a regular Amsler test, BCVA assessment, biomicroscopy slit-lamp examination, fundus examination with a panfundoscopic contact lens, and indirect ophthalmoscopy.

Cross-sectional images of the macular region were obtained along the horizontal plane through the foveal center using SD-OCT (RTVue-XR platform SD-OCT, Optovue, Inc., Fremont, CA, USA), and the axial lengths were measured using partial coherence laser interferometry (Zeiss IOL Master 700; Carl Zeiss Meditec AG, Oberkochen, Germany).

The presence of PS in the study group was confirmed using B-scan ultrasonography (ultrasounds A and B; Quantel

Medical. Du Bois Loli, Auvergne, France) and indirect ophthalmoscopy.

Preoperative and postoperative microstructural evaluations were performed using SD-OCT (RTVue-XR platform SD-OCT, Optovue, Inc., Fremont, CA, USA; Spectralis OCT, Heidelberg Engineering, Heidelberg, Germany) and the swept-source DRI OCT Triton device (Topcon Medical Systems, Inc., Oakland, USA). Cross-sectional images of the macular region were acquired along the horizontal plane through the foveal center, whereas postoperative multimodal functional evaluations were conducted with BCVA and conversion in the logarithm of the minimum angle of resolution (logMAR) units and macular perfusion status evaluation. When the patients underwent macular surgery, the OCT angiography evaluation technology was not available. Postoperative perfusion and VD qualitative evaluations were performed using an OCT angiography device (RTVue XR OCT Avanti with AngioVue Software by Optovue, Inc., Fremont, CA, USA), and the AngioVue OCT angiography system was used for imaging. This system uses a split-spectrum amplitude-decorrelation angiography software algorithm and acquires 70 000 A-scans/s to compose OCT angiography volumes comprising  $304 \times 304$  A-scans. The system achieves high axial resolution at depths up to  $5 \mu\text{m}$  while accounting for motion artifacts. Each OCT angiography cube scan consisted of  $304 \times 304$  A-scans within a  $3\text{-mm} \times 3\text{-mm}$  square centered on the fovea, yielding 304 b-scans. Each b-scan output displayed an average of at least two scans. The AngioVue software program includes a built-in projection artifact removal algorithm with four default en-face retinal imaging settings for automatic segmentation of the superficial vascular plexus (SVP), deep vascular plexus (DVP), outer retina layer, and choriocapillaris plexus. Auto-segmentation errors were corrected using automated adjustment of the contour and location of each segmentation line. The signal strength index was used to assess the quality of the angiographic images.

We qualitatively evaluated the characteristics of the foveal avascular zone (FAZ) in the SVP by analyzing en-face images saved as PNG files using the AngioVue system. Each FAZ area was automatically outlined following AngioAnalytics with angiometrics in the AngioVue software system. Only scans with a signal strength index  $> 46$  were included. Projection artifacts were automatically excluded when digitally outlining the FAZ in the SVP. The superficial FAZ area was qualitatively evaluated and not quantitatively evaluated. VD was evaluated only in the SVP [22, 23] using the AngioVue tool. We defined VD as the proportion of vessel area with blood flow exceeding the total macular area qualitatively evaluated. Whole-macula VD and choriocapillaris foveal flow patterns were qualitatively characterized as normal or lower by comparison with the perfusion characteristics of the control eyes.

### 2.3. Surgical Procedures

Standard 25-G three-port pars plana vitrectomy was performed by one of the authors (MAQR) on the three eyes under local anesthesia and sedation. In addition to core vitrectomy, triamcinolone acetonide-assisted (Kenalog 40 mg/mL; Bristol-Myers, New York, NY) removal of the cortical vitreous from the surface of the retina was performed using a silicone-tipped cannula and active suction, with a focus on achieving a free and mobile posterior hyaloid membrane whilst leaving the superficial foveal tissue (foveal roof) untouched. The technique was standardized, and surgical macular evaluation and revision were performed in all cases using trypan blue ophthalmic solution (0.15%; Membrane Blue, Dutch Ophthalmic, USA) as an adjuvant dye to stain cortical vitreous remnants or ERMs. As a second-step macular surgery, 0.15 mL of 0.25 mg/mL (0.025%) diluted isomolar solution (pH 7.4) of brilliant blue G (BBG) dye was used to selectively stain the ILM and manipulate it carefully to accomplish adequate fovea-sparing surgical ILM removal, without peeling the dyed foveocentral ILM. In all three cases, the ILM was peeled off, leaving the fovea untouched with its corresponding foveocentral ILM, as previously mentioned. This procedure was performed using a 25-G vitrectomy cut and suction instrument (Alcon Constellation Vision System, Alcon Labs; Fort Worth, Texas, USA) and 25-G 0.44 ILM forceps (Grieshaber Revolution DSP ILM forceps; Alcon Labs; Fort Worth, Texas, USA) along with a 25-G Finnesse ILM flex loop microinstrument (Grieshaber, Alcon Labs, Fort Worth, Texas, USA) to facilitate ILM flap manipulation. A non-expandable bubble with a 15% perfluoropropane gas mixture was used as a long-acting tamponade.

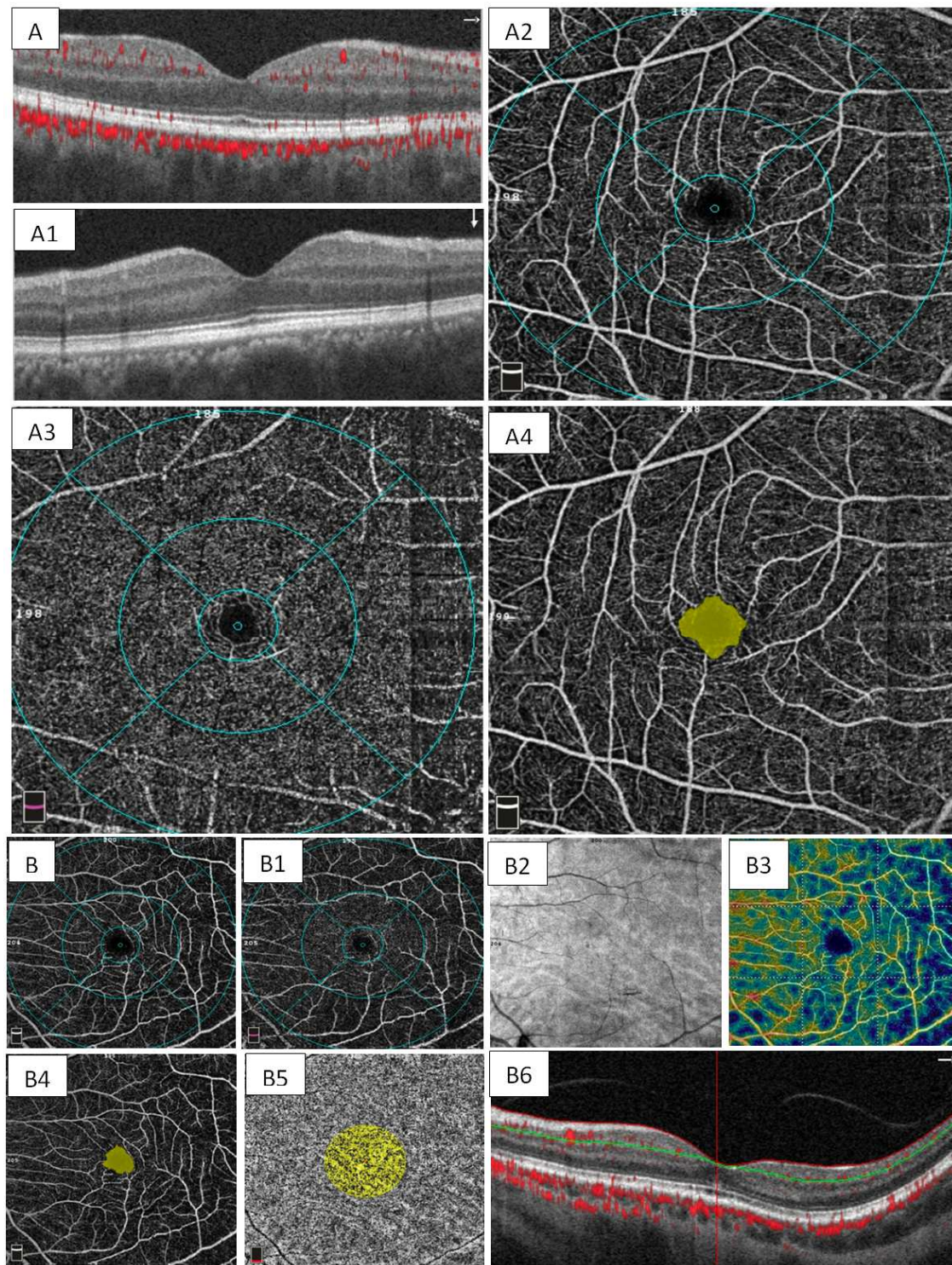
### 2.4. Study Outcomes

The primary outcomes of the study were qualitative postoperative OCT angiographic findings of fully resolved myopic FRD in the surgical group. The secondary outcomes were long-term final postoperative BCVA in the surgical group and its correlation with SD-OCT and angiography findings.

## 3. Results

A total of five eyes of five patients were enrolled in the study, including one normal emmetropic eye and one healthy highly myopic eye as controls (Figure 1), and three structurally fully resolved myopic FRD eyes (Figure 2) followed during a long-term postoperative period (mean follow-up time 59.3 months). The mean age of the participants was 53.3 (range: 46–68) years, and all were women. The patients' general and demographic data stratified by study and control groups are shown in Table 1.



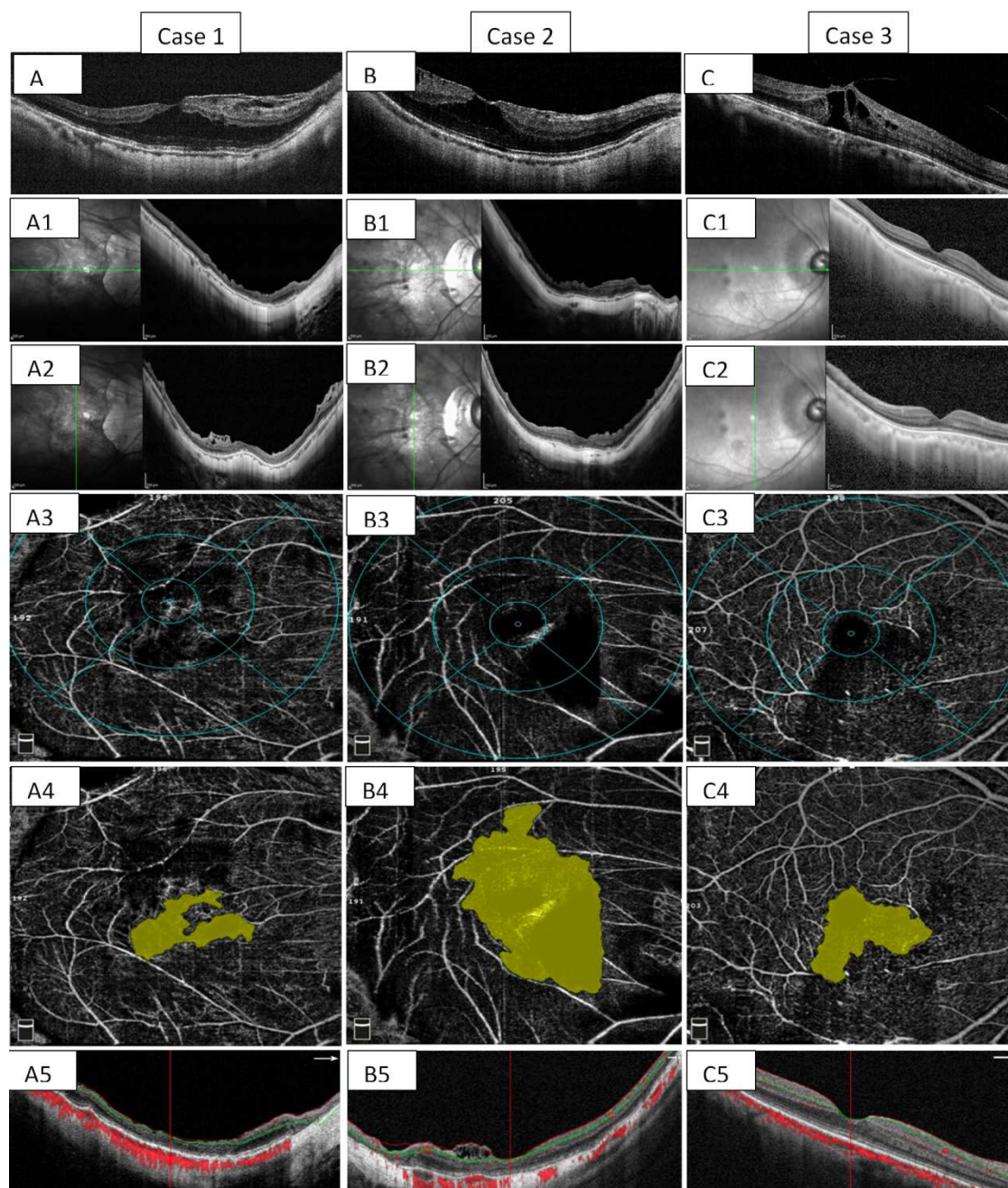


**Figure 1.** Normal emmetropic and myopic control eyes.

A normal SD-OCT crossline in an emmetropic eye; the red dots indicate intraretinal vascular structures and choriocapillaris vascular flow (Figure 1 A, 1 A1). Superficial and deep normal vascular plexus are shown (Figures 1 A, 1 A3). The foveal avascular zone is regular and normal in size (Figure 1 A4). B. SD-OCT horizontal B-scan of a healthy myopic eye; the green line indicates a segmentation line between the inner and outer retina. A normal en-face image is depicted (Figure 1 B1). Normal

SVP and DVP (Figures 1 B2, 1 B3). Corresponding large but normal superficial FAZ in a healthy myopic eye (Figure 1B4). Normal SD-OCT, with red dots representing intraretinal vascular structures and choriocapillaris vascular flow, corresponding horizontal SD-OCT B-scan with green and red segmentation lines depicting a normal retina surface and well-delineated inner and outer retina layer with well-defined outer retina layers biomarkers (Figure 1 B5).





**Figure 2.** Three surgical cases.

Preoperative SD-OCT image of myopic FRD in a very symptomatic highly myopic 49-year-old patient with an axial length of 31.66 mm (Figure 2 A). Corresponding long-term postoperative crossline SD-OCT showing some areas of extrafoveal chorioretinal atrophy, diffuse retinal thinning, some DONFL in the horizontal view and posterior hyaloidal remnants on the vertical view (Figures 2 A1 and A2). Figure A3 superficial vascular plexus (SVP) showing irregular and deficient vascular flow qualified lower than normal average pattern. A4 shows a postoperative large and irregular foveal avascular zone (FAZ). A5 shows that horizontal SD-OCT reveals a complete resolution of the foveal FRD; green and red segmentation lines depict diffuse retinal thinning of the inner

retinal layers. There is some residual schisis on the nasal side, lack of red dots due to vessels deficiencies in the superficial layers and deep red dots consistent with choriocapillaris circulation. Preoperative image shows the OCT horizontal view of a very symptomatic 65-year-old woman with 12 months of loss of vision and severe metamorphopsia on the right eye, there is a very complex submacular foveoretinal detachment (FRD), schisis-like retinal thickening with schisis in the inner nuclear layer on the nasal aspect of the fovea, the external biomarkers such as ellipsoid zone and external limiting membrane are severely disrupted (Figure 2 B). postoperative SD-OCT crossline with a complete resolution of the FRD and some DONFL defects (Figure 2 B1, B2). SVP

shows vascular deficiencies (Figure 2 B3). The FAZ looks quite enlarged and irregular in shape (Figure 2 B4). Long-term SD-OCT with residuals of posterior hyaloid tissue (Figure 2 B5). Preoperative horizontal B-scans of a symptomatic highly myopic eye of a 46-year-old female patient with a very complex myopic foveoretinal detachment and severe altered outer retinal layers, there is abundant amount of intraretinal middle layer fluid within the schisis cavities, axial length of 28.70 mm (Figure 2 C). Postoperative crossline SD OCT with anormal profile (Figures 2 C1 and C2). After an uneventful macular surgery, the SVP showed qualitative deficiencies according to the ETDRS-like sectors grid overlay (Figure 2 C3) with an irregularly large FAZ (Figure 2 C4). The last SD-OCT depicts a nice postoperative foveal profile with some inner retinal thinning on the nasal side (Figure 2 C5).

### 3.1. Statistical Structural Results

The mean preoperative evolution time of FRD was  $6.64 \pm 3.68$  months. The mean postoperative time for myopic FRD resolution was  $4.6 \pm 1.98$  weeks. Surgical intervention resulted in a significant improvement from preoperative BCVA ( $M=0.8801 \pm 0.1485$  logMAR) to postoperative BCVA ( $M=0.3614 \pm 0.2043$  logMAR; permutation  $P < 0.001$ ). [24]

To determine whether surgical outcomes were associated with the macular alterations observed on OCT, the postoperative BCVA was compared between three eyes with abnormal OCT and two eyes with normal OCT evaluation. A one-sided permutation test [25] revealed strong statistical evidence ( $P=0.00245$ ) for the difference in BCVA between those with abnormal OCT and those with normal OCT, with significantly higher BCVA ( $M=0.4446 \pm 0.1869$  logMAR) in the abnormal group than in eyes with normal OCT.

### 3.2. Structural and Qualitative Perfusion Results

The structural and functional findings were analyzed and interpreted by two co-authors (who were masked to avoid bias). Cases 1 and 2 developed localized mild extrafoveal retinal pigment epithelial (RPE) atrophy. The OCT changes in these cases (Figure 2) were consistent with the damage observed in the outer retinal layers and disruption of the photoreceptors. These changes were demonstrated by loss of regularity of IS/OS (ellipsoid zone) and external limiting membrane SD-OCT biomarkers with some degree of irregular and atrophic RPE healing. The perfusion evaluation showed different degrees of perfusion abnormalities at the level of superficial and deep vascular plexuses characterized by a lower-than-normal qualitative VD evaluation with enlargement and irregularities of the FAZ and moderately abnormal choriocapillaris flow patterns considered lower than normal (control and postoperative SD-OCT and OCT angiographic findings are summarized in Table 1).

## 4. Three Relevant Surgical Cases

### 4.1. Surgical Case 1

A 49-year-Old symptomatic woman complained of

metamorphopsia and progressive visual loss in her right eye for 7 months. Her preoperative right eye visual acuity was 20/160 (logMAR 0.90) with a refractive defect of  $-24+3.00 \times 70$  and applanation ocular tension of 10 mmHg. The right eye had an axial length of 31.66 mm with PS and myopic FRD. Preoperative SD-OCT findings were consistent with ERM proliferation, schisis-like macular thickening, and a remarkable quantity of central subretinal macular fluid with disruption of the outer biomarkers on SD-OCT (Figure 2 A). Macular surgery was performed using the fovea sparing ILM peeling technique. Because of the refractory myopic FRD and increased foveal symptomatology, she underwent a second procedure employing macular surgical revision using a BBG dye as an adjuvant to identify ILM remnants, air-fluid exchange, and a non-expandable 15% perfluoropropane gas mixture. Finally, long-term, postoperative crossline SD-OCT evaluation without evidence of residual macular epiretinal membrane was observed on the superficial aspect of the macula (Figure 2 A1, 2 A2). After a 65-month follow-up, the foveomacular region remained attached, with a final BCVA of 20/40 (logMAR 0.30 equivalent); the SVP was defined as lower than normal (Figure 2 A3) with an abnormally irregular FAZ (Figure 2 A4). There was diffuse retinal thinning with a small amount of SRF on the nasal side and some intraretinal vascular deficiencies (Figure 2 A5).

### 4.2. Surgical Case 2

A 65-year-old symptomatic woman presented with aggravated metamorphopsia, a progressive decline in central vision, and high myopia. She had PS in both eyes. The right eye, with an axial length of 30.62 mm underwent macular surgery because of a 12-month history of symptomatic FRD (Figure 2 C). The preoperative BCVA was 20/100 (logMAR 0.70); this eye underwent a 25-G pars plana vitrectomy with a fovea-sparing ILM peeling technique. Fluid-air gas exchange was performed using 15% C3F8 tamponade. After an 89-month longitudinal follow-up, autofluorescence imaging of the operated eye revealed only fine and very mild foveocentral pigment mottling, evidence of fovea-sparing ILM and faint localized central autofluorescence due to RPE thinning. Postoperative BCVA was 20/25 (logMAR 0.10), with no evidence of recurrent myopic FRD or progression to MH on the different postoperative SD-OCT crossline horizontal and vertical evaluations (Figure 2 C1, 2 C2). The SVP flow pattern showed some vascular deficiencies considered as lower than normal (Figure 2 C3) with a corresponding FAZ appearing enlarged and irregular in shape (Figure 2 C4); the corresponding postoperative choriocapillaris flow pattern was abnormal. The long-term postoperative SD-OCT horizontal evaluation scan showed diffuse thinning of the inner retinal layer corresponding to the irregular reduced flow area and some posterior hyaloidal remnants (Figure 2 C5).

### 4.3. Surgical Case 3

A 46-year-old woman with 3 months of persistent,

bothersome, and disabling metamorphopsia, high myopia, and PS underwent 25-G three-port pars plana vitrectomy and macular surgery on the phakic right eye for myopic FRD (Figure 2 C). The patient underwent uneventful macular surgery comprising BBG dye-assisted fovea-sparing ILM peeling technique and a 15% C3F8 long-acting non-expandable gas tamponade. The preoperative BCVA was 20/200 (logMAR 1.00), with PS and an axial length of 28.70 mm. After a 24-month follow-up, the final postoperative BCVA was 20/25 (logMAR 0.10). This eye developed mild media lens-induced opacity and mild peripapillary pigment atrophy without evidence of foveal RPE alteration with some superficial DONFL defects in the en-face SD-OCT crossline

long-term postoperative structural evaluation. Uneventful cataract extraction with in-the-bag lens implantation (Figure 2 C1 and 2 C2) was performed. Long-term macular perfusion evaluation revealed an SVP flow pattern with qualitative perfusion deficiencies considered lower than normal mainly inferior to the fovea (Figure 2 C3) and an enlarged and irregular qualitatively abnormal FAZ (Figure 2 C4). The corresponding long-term postoperative SD-OCT structural evaluation revealed a normal OCT profile with thinning of the inner retinal layer, predominantly on the inferotemporal side (Figure 2 C5).

A summary of the preoperative and postoperative structural and functional findings of the three eyes are presented in Table 1.

**Table 1.** Summary of preoperative and postoperative structural, functional and perfusion (OCT angiography) findings.

Findings in study group:	CASE 1 (49 F)	CASE 2 (65 F)	CASE 3 (46 F)	Observations
Evolution of FRD	7 months	12 months	3 months	Mean 7.3 months
Follow-up	65 months	89 months	24 months	Mean 59.3 months
Preoperative BCVA	LogMAR 0.90 (20/160)	LogMAR 0.70 (20/100)	LogMAR 1.00 (20/200)	
Postoperative BCVA	LogMAR 0.30 (20/40)	LogMAR 0.10 (20/25)	LogMAR 0.10 (20/25)	P<0.0001
Preoperative SD-OCT	FRD+foveoschisis+MER	FRD+foveoschisis+MER	FRD	All symptomatic FRDs
Axial length	31.66 mm	30.62 mm	28.70 mm	
Findings in control groups				
Emmetropic patient (54 M)	20/20	Axial length 22.2 mm	Normal SD-OCT	Normal OCT angiography
Normal myopic eye (59 F)	BCVA 20/20	Axial length 29.82 mm	Normal SD-OCT	Normal OCT angiography
POSTOPERATIVE ESTRUCTURAL EVALUATION (study eyes)				
SS and SD-OCT:				
CSFT	Less than 220 $\mu$ m	Less than 210 $\mu$ m	Up to 220 $\mu$ m	Irregular CSFT
Foveal contour	Abnormal	Abnormal	Recovered and normal	OCT profile
ERM	Mild, inferotemporal to the fovea	No	No	residuals
Residual SRF	Residual nasal to fovea	No	No	Non-symptomatic
Residual foveoschisis	Nasal and extrafoveal	No	No	Denied additional surgery
IS/OS (subfoveal ellipsoid)	Moderate disruption	Mild disruption	Recovered	In a long-term OCT evaluation
RPE status	Mild central atrophy	Faint central atrophy	Preserved	RPE thinning
DONFL (dimples)	Mild dimples	Isolated dimples	Mild dimples on En-face OCT	Quite evident in the three cases
LONG-TERM POSTOPERATIVE MACULAR PERFUSIONAL EVALUATION STATUS				
OCT angiography:				
Superficial FAZ	Enlarged, irregular	Enlarged, irregular	abnormal	
SVP pattern	lower	lower	lower	
DVP pattern	lower	lower	Normal	
Choriocapillaris flow pattern	Reduced	Reduced	Normal	

## 5. Discussion

MF and myopic FRD may be responsible for slowly progressive visual loss and severe visual disturbances in MTM eyes at the subclinical and clinical levels, respectively. Our OCT angiography perfusion findings revealed structural and perfusion phenotypes in a sample of three surgically resolved myopic FRD eyes with MTM. The obtained morphological, structural, and vascular perfusion measurements suggest the perfusion mechanisms underlying MTM.

Increased VD reflecting compensatory recalibration of perfusion might offer protective effects in eyes with MF and prevent progression to more advanced stages of myopic FRD [26] with some hypothetical absence of structural consequences. Our study suggests that symptomatic highly myopic patients in the early stages of MTM might benefit from a timely, well-planned, non-complicated macular surgery

with an elevated incidence of myopic FRD resolution preferably achieved with a modified foveocentral-saving ILM technique to reduce the risk and progression to more advanced stages of MTM [27, 28].

Wang *et al.* [26] described a possible compensatory autoregulatory mechanism in the choroidal perfusion support, which is demonstrated by increased VD in the choroid capillary layer that may assist in maintaining the MF and prevent its progression to FRD. Previously, only lower macular sensitivity detected with microperimetry was reported in highly myopic eyes without detachment, suggesting the use of this functional technique for longitudinal surveillance of the retina to predict myopic pathology before the loss of vision [29].

In our study, we were unable to confirm this compensatory incremental choroidal VD finding at the SVP, DCP, or the choroidal capillary layer. We observed decreased choroidal perfusion in myopic eyes in accordance with the report by

Al-Sheikh et al. [30], and enhanced depth imaging OCT revealed choroidal thinning in the macular region as an age-related degenerative change described in high myopia [31, 32, 33]. We hypothesized that in the early stages of MTM, decreased subfoveal choroidal thickness may precede the development of retinoschisis. However, in this study, we did not directly measure or quantify subfoveal choroidal thickness. Poor choroidal support of Müller cells and consequent development of elongated fibrils may also contribute to the development of myopic retinoschisis [26].

Some studies have described the role of Müller cell integrity in traction maculopathies because MTM is a pathology of Müller cell cones that involves both inner tractions from the ILM and outer stretch forces from the posterior staphyloma, according to Wang et al. [26]. Retinoschisis is associated with substantial structural changes in Müller cells [33]. Increases in the sizes of cavities and associated alterations in mechanical stretch forces may damage Müller cells and impair their function [34], mediating visual impairment in eyes with early-stage MTM.

Some surgical results indicated that reorientation of the abnormal architecture of the Müller cell fibrils by releasing traction and resolving the internal/external MF and flattening the myopic FRD is of paramount importance for improving or restoring visual acuity in eyes during the early stages of MTM. As the foveal ILM is a component of the foveal Müller cell fibril, its surgical preservation may prevent further progression to more advanced stages of MTM [27, 28, 35].

The reduced visual acuity associated with the early stages of MTM is assumed to be the result of foveal distortion rather than disruption of photoreceptors in MF as well as due to photoreceptor disruption and chronic photoreceptor separation from the RPE in myopic FRD. This is because of the presence of chronic subretinal fluid with a loss of nourishment accompanied by the consequent photoreceptor damage in myopic FRD; we observed it to be related to the loss of the EZ integrity seen in the preoperative and postoperative structural SD-OCT evaluation that was not found in the healthy highly myopic control eye.

Therefore, care should be taken to avoid diminishing choroidal perfusion (as reflected in VD) in eyes at an advanced stage of MTM (such as MH and MHRD) by surgeries (e.g., macular buckling) that result in the compression of the choroid and reduction in choroidal perfusion [26]. FAZ distortion and enlargement have been reported to contribute to decreased VD in MF. Visual acuity deficits arising due to myopic FRD should be corrected by removing the mechanical stretching forces, for example, by peeling off the epiretinal membrane, posterior hyaloid, and parafoveolar ILM. Unlike the study by Wang et al. [26], we did not establish associations between BCVA and quality of macular perfusion in the SVP and the choroid capillary layer in the fully resolved myopic FRD due to MTM at the end of follow-up, or in the healthy highly myopic eye, suggesting that choroidal thickness itself may not directly affect vision.

In a large case series [13], Panozzo and Mercanti concluded that surgical resolution of vitreoretinal traction during the early stages of FRD would enable re-flattening of the macula center,

thereby preventing the development of a full-thickness MH and emphasizing the high prevalence of ERMs in highly myopic eyes with MF and FRD; however, this large case series lacked both quality perfusion evaluation and also qualitative evaluation by means of fluorescein angiography; therefore, at the time of the writing of this manuscript, only the mechanical tractional alteration had been hypothesized without addressing the role of possible macular and choroidal perfusion abnormalities. Choroidal perfusion support, which is indicated by increased VD in the choroid capillary layer, may help maintain a stable MF with a low rate of MTM progression and prevent FRD formation [26]. Al-Sheikh et al. [30] suggested that decreased choroidal perfusion and a lower VD flow pattern quality in myopic eyes with a reduced whole-macular VD pattern can be attributed to the mechanical stretch forces caused by the elongation of the eyeball.

Quantitatively, VD evaluations of macular microcirculation are of paramount clinical importance, because even mild changes in microcirculation could lead to pathological changes with impact on vision quality [36]. Small vessel changes with lower VD values have been identified in multiple retinal vascular diseases, including diabetic retinopathy, macular telangiectasia, and radiation retinopathy [37-39].

In this study, owing to the reliability and reproducibility of OCT angiography perfusion testing, we were able to report comprehensive qualitative OCT angiographic evaluation findings. Therefore, we report novel findings regarding associations between normal range vessel changes not only in normal emmetropic and healthy highly myopic eyes, but also in eyes with a fully surgically resolved myopic FRD. Our results indicate non-significant clinical differences in macular perfusion between the normal control eyes; however, we did observe significant perfusion differences in the qualitative VD evaluations in the eyes post-surgery. VD evaluations of macular microcirculation revealed highly significant clinical differences between healthy eyes and surgically resolved myopic FRD eyes. Together, these findings suggest that there is a relationship between tractional and perfusion mechanisms, although establishing causality might prove difficult at this stage of research.

Similar to You et al. [40], we observed that the qualitative impressions of paracentral subfields were not affected by the FAZ and that FAZ had less effect on the evaluation of the whole macular area. This result caused us to conclude that the qualitative evaluation needs to be complemented with quantitative evaluation of macular VD in the paracentral macular area in order to be reliable for assessing the vascular whole macular area. Recently, Peng et al. [41] also speculated that the resolution of myopic FRD after foveal-sparing ILM removal technique was driven by upregulated local cytokine production, thereby implicating the vascular microenvironment at that fundamental level together with alterations in the permeability of the microcirculation in patients with MTM. Our study provides insights into the early stages of MTM, indicating that in its tractional pathogenesis, there are also contributory factors at the microcirculatory level.



## 6. Conclusion

The OCT angiography is a relatively new approach to detect flow alterations and perfusion abnormalities in the myopic macula, prior to the appearance of structurally or clinically changes allowing the clinicians to improve patient care by earlier detection and better planned intervention. We think our findings will likely generalize to other angio OCT systems. In addition, larger scan patterns are required to adequately quantify macular perfusion indices deficits in myopic FRD, and this problem will be solved in time by technology. The results revealed postoperative microstructural abnormalities on SD-OCT with VD qualitative deficiencies in the superficial vascular complex of the macula with FAZ abnormalities in surgically resolved myopic FRD traction maculopathy.

## 7. Recommendation

We acknowledge the limitations of our case series report, including the relatively small number of eyes, which limits the statistical power of the study that would allow us to detect associations between visual acuity and VD measurements.

Our study also lacked quantitative and critical statistical evaluations. This was primarily related to the strict exclusion criteria we applied to limit our study of successful surgery eyes with early stages of MTM in a long-term assessment. The study also lacks serial data and longitudinal analysis. Nevertheless, the study has the benefits of combining SD-OCT and OCT angiography evaluation with the examination of qualitative perfusion phenotypes. Given the lack of OCT angiography data in published studies on perfused macular assessment in the early stages of MTM and postoperative perfusion status of the macula in highly myopic eyes, we anticipate that these data will be of interest in the field.

Further investigations, including histopathologic studies, with appropriate quantitative evaluations, are required to confirm the role of perfusion macular mechanisms in the pathogenesis of MF/FRD due to MTM. These studies would aid in elucidating the role of microvascular perfusion mechanisms in maintaining Müller cell integrity in traction maculopathies. MTM is a pathology of Müller cell cones that involves both inner traction from the ILM and outer stretch forces from the posterior staphyloma. Therefore, in-depth research on the perfusion mechanisms is required in the future, preferably by combining quantitative perfusion measurement techniques and histopathologic studies within a longitudinal framework in individual patients as well as larger synthetic group trajectories.

## Declarations

### *Ethics Approval and Consent to Participate*

This study adhered to the tenets of the Declaration of Helsinki, received full ethical approval from the research ethics committee, and was approved by the institutional review committee and the teaching department of the institution enrolled (no reference numbers were provided for retrospective studies by this institution). Written informed consent was obtained from all

patients in accordance with the institutional guidelines.

### *Consent for Publication*

Written consent was obtained from all patients.

### *Availability of Data and Materials*

The dataset supporting the conclusions of this article is available in the retina service of the Retina Specialists repository file at the Institute of Ophthalmology in <http://www.ofthalmologiainteralabc.com/retinaspecialists>. The dataset supporting the conclusions of this article is included within the article.

### *Competing Interests*

The authors declare that they have no competing interests.

### *Authors' Contributions*

MAQR, Surgeon in Chief, study conception, writing the manuscript, dataset interpretation, final revision, conclusions; EAQG, figures artwork, tables, statistics; JMN, photographic material compilation, statistics; BMA, assistant surgeon, photographic material compilation ANJ, assistant surgeon, photographic material compilation and FGW, final revision. All authors have approved the manuscript for submission.

### *Co-Authors Affiliation*

All co-authors are affiliated to the Faculty of Medicine in the Postgraduate Division at NATIONAL AUTONOMOUS UNIVERSITY OF MEXICO. Mexico City, Mexico.

## Acknowledgements

We express our deep appreciation to the technical staff of the participating institution: Retina Service at the Institute of Ophthalmology, “Conde de Valenciana” Foundation, Mexico City, Mexico, which is affiliated to The Postgraduate Division Studies at National Autonomous University of Mexico.

## References

- [1] Morgan IG, Ohno-Matsui K, Saw SM (2012) Myopia. *Lancet*, 379 (9827), 1739-1748.
- [2] Pathological myopia is the fifth-leading cause of low vision or blindness in Japan and the second-leading cause among people aged over 40 years in China.
- [3] Iwase A, Araie M, Tomidokoro A, Yamamoto T, Shimizu H, Kitazawa Y (2006) Prevalence and causes of low vision and blindness in a Japanese adult population: the Tajimi Study. *Ophthalmology*, 113 (8), 1354-1362. <https://doi.org/10.1016/j.ophtha.2006.04.022>.
- [4] Flitcroft DI, He M, Jonas JB, Jong M, Naidoo K, Ohno-Matsui K (2019) IMI Defining and classifying myopia: A proposed set of standards for clinical and epidemiologic studies. *Investigative Ophthalmology & Visual Science*, 60 (3), M20-M30. doi: 10.1167/iov.18-25957.

- [5] Ruiz-Medrano J, Flores-Moreno I, Ohno-Matsui K, Cheung CM, Silva R, Ruiz-Moreno JM (2020) Validation of the recently developed ATN classification and grading system for myopic maculopathy. *Retina*, 40 (13), 2113–2118.
- [6] Ohno-Matsui K, Kawasaki R, Jonas JB, Cheung CM, Saw SM, Verhoeven VJ, et al (2015) International photographic classification and grading system for myopic maculopathy Meta-analysis for pathologic myopia (META-PM) study group. *American Journal of Ophthalmology*. 159 (5), 877-883.e7. <https://doi.org/10.1016/j.ajo.2015.01.022>.
- [7] Vitale S, Sperduto RD, Ferris FL 3rd (2009) Increased prevalence of myopia in the United States between 1971–1972 and 1999–2004. *Archives of Ophthalmology*. 127 (12), 1632–1639. <https://doi.org/10.1001/archophthalmol.2009.303>.
- [8] Wang SW, Hsia Y, Huang CJ, Hung KC, Chen MS, Ho TC, et al (2021) Biomarkers in the pathogenesis of epiretinal membrane and myopic traction maculopathy: effects of internal limiting membrane incompliance and posterior staphyloma. *Photodiagnosis and Photodynamic Therapy*, 33, 102208. <https://doi.org/10.1016/j.pdpdt.2021.102208>.
- [9] Shimada N, Tanaka Y, Tokoro T, Ohno-Matsui K (2013) Natural course of myopic traction maculopathy and factors associated with progression or resolution. *American Journal of Ophthalmology*, 156 (5), 948–957.e1. <https://doi.org/10.1016/j.ajo.2013.06.031>.
- [10] Shimada N, Ohno-Matsui K, Baba T, Futagami S, Tokoro T, Mochizuki M (2006) Natural course of macular retinoschisis in highly myopic eyes without macular hole or retinal detachment. *American Journal of Ophthalmology*, 142 (3), 497–500. <https://doi.org/10.1016/j.ajo.2006.03.048>.
- [11] Ikuno Y, Tano Y (2003) Early macular holes with retinoschisis in highly myopic eyes. *American Journal of Ophthalmology*, 136 (4), 741–744. [https://doi.org/10.1016/s0002-9394\(03\)00319-2](https://doi.org/10.1016/s0002-9394(03)00319-2).
- [12] Rada JA, Shelton S, Norton TT (2006) The sclera and myopia. *Experimental Eye Research*, 82 (2), 185-200. <https://doi.org/10.1016/j.exer.2005.08.009>.
- [13] Panozzo G, Mercanti A (2004) Optical coherence tomography findings in myopic traction maculopathy. *Archives of Ophthalmology*, 122 (10), 1455-1460. <https://doi.org/10.1001/archophth.122.10.1455>.
- [14] Margolis R, Spaide RF (2009) A pilot study of enhanced depth imaging optical coherence tomography of the choroid in normal eyes. *American Journal of Ophthalmology*, 147 (5), 811-815. <https://doi.org/10.1016/j.ajo.2008.12.008>.
- [15] Panozzo G, Mercanti A (2007) Vitrectomy for myopic traction maculopathy. *Archives of Ophthalmology*, 125 (6), 767-772. <https://doi.org/10.1001/archophth.125.6.767>.
- [16] Takano M, Kishi S (1999) Foveal retinoschisis and retinal detachment in severely myopic eyes with posterior staphyloma. *American Journal of Ophthalmology*, 128 (4), 472-476. [https://doi.org/10.1016/s0002-9394\(99\)00186-5](https://doi.org/10.1016/s0002-9394(99)00186-5).
- [17] Uchida A, Shinoda H, Koto T, Mochimaru H, Nagai N, Tsubota K, et al (2014) Vitrectomy for myopic foveoschisis with internal limiting membrane peeling and no gas tamponade. *Retina*, 34 (3), 455-460. <https://doi.org/10.1097/IAE.0b013e3182a0e477>.
- [18] Ikuno Y, Gomi F, Tano Y (2005) Potent retinal arteriolar traction as a possible cause of myopic foveoschisis. *American Journal of Ophthalmology*, 139, 462-467. <https://doi.org/10.1016/j.ajo.2004.09.078>.
- [19] Ho AC, Yannuzzi LA, Guyer DR, Slakter JS, Sorenson JA, Orlock DA (1994) Intraretinal leakage of indocyanine green dye. *Ophthalmology*, 101 (3), 534-541.
- [20] Hwang TS, Zhang M, Bhavsar K, Zhang X, Campbell JP, Lin P, et al (2016) Visualization of 3 distinct retinal plexuses by projection-resolved optical coherence tomography angiography in diabetic retinopathy. *JAMA Ophthalmology*, 134 (12), 1411-1419.
- [21] OHSU, Study shows new technology may improve management of leading causes of blindness. Portland, OR: Oregon Health & Science University; 2015.
- [22] Klufas MA, Phasukkijwatana N, Iafe NA, Prasad PS, Agarwal A, Gupta V (2017) Optical coherence tomography angiography reveals choriocapillaris flow reduction in placoid chorioretinitis. *Ophthalmology Retina*, 1 (1), 77–91.
- [23] Kuehlewein L, Bansal M, Lenis TL, Iafe A, Sadda SR, Bonini Filho MA (2015) Optical coherence tomography angiography of type 1 neovascularization in age-related macular degeneration. *American Journal of Ophthalmology*, 160 (4), 739–748.e2.
- [24] Hothorn T, Hornick K, van de Wiel MA, Zeileis A (2008) Implementing a class of permutation tests: the coin package. *Journal of Statistical Software*, 28 (8), 1-23. <https://doi.org/10.18637/jss.v028.i08>.
- [25] Garren ST (2017) Permutation tests for nonparametric statistics using R. *Asian Research Journal of Mathematics*, 5 (2), 1-8. <https://doi.org/10.9734/ARJOM/2017/34694>.
- [26] Wang S-W, Hung K-C, Tsai C-Y, Chen M-S, Ho T-C (2019) Myopic traction maculopathy biomarkers on optical coherence tomography angiography—an overlooked mechanism of visual acuity correction in myopic eyes. *Eye (London, England)*, 33 (8), 1305-1313.
- [27] Shimada N, Sugamoto Y, Ogawa M, Takase H, Ohno-Matsui K (2012) Fovea-sparing internal limiting membrane peeling for myopic traction maculopathy. *American Journal of Ophthalmology*, 154 (4), 693-701. <https://doi.org/10.1016/j.ajo.2012.04.013>.
- [28] Shiraki N, Wakabayashi T, Ikuno Y, Matsumura N, Sato S, Sakaguchi H, et al (2020) Fovea-sparing versus standard internal limiting membrane peeling for myopic traction maculopathy: a study of 102 consecutive cases. *Ophthalmology Retina*, 4 (12), 1170–1180. <https://doi.org/10.1016/j.oret.2020.05.016>.
- [29] Wong QY, Dan YS, Go You DJ, Hoang QV, Wong CW (2020). A micropertimetric evaluation of macular function in highly myopic eyes with myopic macular degeneration. *ARVO Annual Meeting Extract. Investigative Ophthalmology & Visual Science*, 61, 2683.
- [30] Al-Sheikh M, Phasukkijwatana N, Dolz-Marco R, Rahimi M, Iafe NA, Freund KB (2017) Quantitative OCT angiography of the retinal microvasculature and the choriocapillaris in myopic eyes. *Investigative Ophthalmology & Visual Science*, 58 (4), 2063-2069.
- [31] Gaucher D, Haouchine B, Tadayoni R, Massin P, Erginay A, Benhamou N (2007) Long-term follow-up of high myopic foveoschisis: natural course and surgical outcome. *American Journal of Ophthalmology*, 143 (3), 455-462. <https://doi.org/10.1016/j.ajo.2006.10.053>.

- [32] Sebag J (2004) Anomalous posterior vitreous detachment: a unifying concept in vitreo-retinal disease. *Graefe's Archive for Clinical and Experimental Ophthalmology*, 242 (8), 690–698.
- [33] Tang J, Rivers MB, Moshfeghi AA, Flynn HW, Jr, Chan CC (2010) Pathology of macular foveoschisis associated with degenerative myopia. *Journal of Ophthalmology*, 2010, 175613. <https://doi.org/10.1155/2010/175613>; 20814547.
- [34] Park S, Lee YJ (2013) Nano-mechanical compliance of Müller cells investigated by atomic force microscopy. *International Journal of Biological Sciences*, 9 (7): 702-706.
- [35] Ho T-C, Yang C-M, Huang J-S, Yang C-H, Yeh P-T, Chen T-C (2014) Long-term outcome of foveolar internal limiting membrane nonpeeling for myopic traction maculopathy. *Retina*, 34 (9), 1833–1840.
- [36] Yu DY, Cringle SJ (2001) Oxygen distribution and consumption within the retina in vascularized and avascular retinas and in animal models of retinal disease. *Progress in Retinal and Eye Research*, 20 (2), 175-208.
- [37] Sakata K, Funatsu H, Harino S, Noma H, Hori S (2006) Relationship between macular microcirculation and progression of diabetic macular edema. *Ophthalmology*, 113 (8), 1385-1391.
- [38] Chin EK, Kim DY, Hunter AA, Pilli S, Wilson M, Zawadzki RJ, et al (2013) Staging of macular telangiectasia: power-Doppler optical coherence tomography and macular pigment optical density. *Investigative Ophthalmology & Visual Science*, 54 (7), 4459-4470.
- [39] Veverka KK, AbouChehade JE, Iezzi R, Jr, Pulido JS (2015) Noninvasive grading of radiation retinopathy: the use of optical coherence tomography Angiography. *Retina*, 35, 2400-2410.
- [40] You QS, Freeman WR, Weinreb RN, Zangwill L, Manalastas PIC, Saunnders LJ (2017) Reproducibility of vessel density measurement with optical coherence tomography angiography in eyes with and without retinopathy. *Retina*, 37 (8), 1475-1482. doi: 10.1097/IAE.0000000000001407.
- [41] Peng M, Wei Y, Zhang Z, Zhang T, Qui S, Fang D (2020) Increased levels of DKK1 in vitreous fluid of patients with pathological myopia and the correlation between DKK1 levels and axial length. *Current Eye Research*, 45 (1), 104-110.