

Case Report

Giant Conjunctival Naevus: Case Report from Bamako

Seydou Bakayoko¹, Seydou Diallo^{1,*}, Rodrigue Romuald Elie Gagnan Yan Zaou Tou^{1,*}, Adama Guindo¹, Brainima Coulibaly¹, Jean Michel Mbaïkoua², Mahamat Adam Dicko¹, Jean Marc Léré Tiama¹, Mamasile Clement Bagouya¹, Japhet Pobanou Thera¹

¹Institute of African Tropical Ophthalmology, Bamako University of Science and Technology, Bamako, Mali

²National University Hospital Center of Bangui, University of Bangui, Bangui, Central Africa Republic

Email address:

diall907@yahoo.fr (S. Diallo), rodrigueelien@yahoo.fr (R. R. E. G. Y. Z. Tou)

*Corresponding author

To cite this article:

Seydou Bakayoko, Seydou Diallo, Rodrigue Romuald Elie Gagnan Yan Zaou Tou, Adama Guindo, Brainima Coulibaly, Jean Michel Mbaïkoua, Mahamat Adam Dicko, Jean Marc Léré Tiama, Mamasile Clement Bagouya, Japhet Pobanou Thera. Giant Conjunctival Naevus: Case Report from Bamako. *International Journal of Ophthalmology & Visual Science*. Vol. 4, No. 4, 2019, pp. 63-65. doi: 10.11648/j.ijovs.20190404.11

Received: August 24, 2019; **Accepted:** September 23, 2019; **Published:** October 9, 2019

Abstract: Conjunctival naevus is a common tumour in the conjunctiva. It can appear clinically in childhood or adolescence. The juxta limbic location (on the temporal side and near the palpebral fissure) of the naevus is the most frequent. Its presence at the level of the lacrimal caruncle (inner angle of the eye) and the semi-lunar fold (outside the caruncle) is more rare. Their pigmentation varies with age. Thus, almost 25% of them are amelanotic (especially in children). The pigmentation varies according to several factors: the congenital character of these naevi; hormonal changes during pregnancy; intense exposure to the sun. In addition, a change in pigmentation can be observed in almost 25% of cases with inflammation, or in cases of intense activity of melanophages. The size of the naevi tends to increase with age. This is usually done after puberty. We report a case of a 2-year-old boy with a pigmented conjunctival naevus about 2 cm long, flat, limbal and bulbar juxta at the temporal side. The rest of the eye exam is normal. The child has been entrusted to the team of the orbito-palpebral surgery and the annexes for the continuation of the management. We will present its clinico-histological and therapeutic aspects.

Keyword: Conjunctival Naevus, Congenital, Infant, Mali

1. Introduction

Naevus are the most frequent tumours of the ocular surface. In the series published by Shields, it represents 28% of conjunctival tumours and 52% of melanocytic tumours [1]. The naevus consists of naevic cells arranged in thecae. These thecae are initially located at the junction between the epithelium and the chorion. As the evolution progresses, the thecae descend into the chorion and lose their connections with the epithelium. A naevus located at the epithelium-chorion junction is called a naevus jonctionnel, whereas a naevus exclusively located at the level of the chorion will be called a naevus sous-épithélial or intrastromal. When the proliferation is both junctional and sub-epithelial, it is called compound naevus [2]. Conjunctival naevus is a

congenital tumor classified as hamartoma or an acquired tumor included in neoplasia. It may be present clinically at birth or appear during the first or second decade. It presents as a flat or sessile lesion with a very discrete relief, achromic with pinkish appearance in 15 to 20% of cases, partially pigmented in 20 to 30% and fully pigmented in 50 to 65% of cases. Intralésionary cysts are common between 60% and 70% of cases. In about one in three cases, a thin vascular network can be seen within the lesion (21-38%) or the presence of dilated feeding vessels (27-33%) [3, 4]. We present a case of unilateral right conjunctival naevus.

2. Observation

He is a 2-year-old boy, 3rd child of a sibling of 03 children from a consanguineous marriage, with no specific personal and family pathological history. The child was brought in for consultation by his mother for a black spot observed since birth that slowly increases in size. Examination with the slit lamp of the right eye finds a pigmented Naevus conjunctiva about 2 cm long, flat, juxta limbic and bulbar at the level of the temporal side. The rest of the eye exam is normal. A photograph of the anterior segment is taken (Figure 1) and rigorous monitoring is restored, because the risk of malignant transformation into connective malignant melanoma is possible even if it is rare, followed by referral to the orbito-palpebral surgery team for the continuation of management.

3. Discussion

The conjunctival naevus is a benign congenital tumour. The risk of malignant transformation is actually extremely low, below 1% [5]. The diameter of the naevus is on average 4 mm but can vary from 0, 2 to 30 mm. Giant lesions (diameter greater than 10 mm) account for 5% of cases [6]. In our study the diameter of the naevus is about 10 mm. In our study the conjunctival naevus is pigmented. Their pigmentation may vary (brown, tan, blue) [7]. The limbic and bulbar location of the conjunctival naevus in our study is noted in the literature [3]. Considering the clinico-morphological appearance (large size and variegate pigmentation), these lesions can cause differential-diagnostic difficulties as they can be confused with malignant melanoma [8]. Giant nevi represent a rare sub-group of melanocytic conjunctival alterations. Considering the extended conjunctival involvement and variegated clinic-morphological appearance. In case of amelanotic naevi, OCT can provide helpful additional information to improve diagnostic accuracy. Frequent misdiagnosis of amelanotic naevi can lead to unnecessary anti-inflammatory treatment (scleritis, episcleritis, pinqueculitis are the most important differential-diagnostic pathologies).

Its histologic description is as follow [9]:

Nevomelanocytes organized into intraepithelial nests of oval cells (type A), sheets of oval to cuboidal cells (type B), and spindled cells in subepithelium (type C). Often (50%) with solid and prominent cystic inclusions of conjunctival epithelium and chronic inflammatory infiltrate. May have atypical features and mitotic figures during growth periods

a) *Compound* (70 - 78%):

Most common, nevi cells in epithelium and subepithelial connective tissue, cells have cysts lined by cuboidal and goblet cells and intranuclear inclusions, may have large pigmented cells with prominent basophilic nucleoli and usually mixed inflammatory cells.

b) *Junctional* (5%):

Contiguous nests of round / spindle melanocytes near basal cell region with oval nuclei, small nucleoli, nucleoli may be

basophilic and prominent but no atypia, uncommon except in young children and resembles primary acquired melanosis with atypia.

c) *Subepithelial* (9%):

Nevus cells only in subepithelial connective tissue, no pigment, bland nuclei and may have clear cytoplasm due to lipid and central round nucleus (balloon cell nevus).

Carol L. Shields and all have found that the compound and junctional nevi concern that young subjects whereas the subepithelial and blue nevi were highly in elderly person [10].

For the treatment of conjunctival naevus, there is two options:

a) A surgical excision combined with an Amniotic Membran Transplantation [11] is effective and economical for the treatment of large conjunctival lesions. Advantage for surgical treatment is the possibility for histological analysis, especially to patients with the "ABCDE rule". The ABCDE rule includes several clinical melanoma features: Asymmetry, Border irregularity, Color variation, Diameter greater than 6 mm, and Evolution (changes in size, shape, or elevation) [12].

b) Laser Treatment of Conjunctival Nevus [13] after administration of proparacaine hydrochloride 0.5%, the laser was focused on the area of nevus directly. The laser is set as spot size 200 um, duration of the laser pulse 0.1 second, and the energy ranged from 300 mW to 350 mW. The Argon laser photoablation is an alternative treatment for conjunctival nevi. Some have claimed it is safe, fast, and more economical [13]. Advantages of the argon laser ablation include the lack of sutures, less pain, no scarring, and a uneventful recovery period [14].

4. Conclusion

Conjunctival naevus may exhibit a variation in location, pigmentation and size. It is a benign tumour most often diagnosed in children and adolescents. It requires regular follow-up because transformation into malignant melanoma is possible even if it is rare.

Conflicts of Interest

The authors declare no conflict of interest.

Authors Contributions

All authors have read and approved the final version of the manuscript.

Acknowledgements

Many thanks to the parents for having accepted the publication of this report case.

Appendix

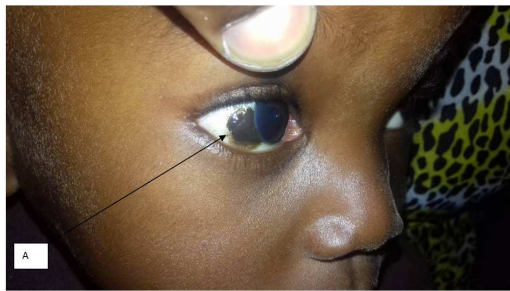


Figure 1. Conjunctival Naevus pigmented unilateral right (A).

References

- [1] Shields CL, Demirci H, Karatza E, Shields JA. Clinical survey of 1643 melanocytic and nonmelanocytic conjunctival tumors. *Ophthalmology* 2004; 111: 1747-54. <https://www.ncbi.nlm.nih.gov/pubmed/15350332>
- [2] Desjardins L. Anatomie pathologique en ophtalmologie. Tumeurs intra-oculaires. Issy-les-Moulineaux: Elsevier Masson/SFO; 2011-2012, p. 61.
- [3] Gerner N, Nørregaard JC, Jensen OA, Prause JU. Conjunctival naevi in Denmark 1960–1980. A 21-year follow-up study. *Acta Ophthalmol Scand* 1996; 74: 334-7. <https://www.ncbi.nlm.nih.gov/pubmed/8883545>
- [4] Levecq L, De Potter P, Jamart J. Conjunctival nevi clinical features and therapeutic outcomes. *Ophthalmology* 2010; 117 (1): 35-40. doi: 10.1016/j.ophtha.2009.06.018. <https://www.ncbi.nlm.nih.gov/pubmed/19896191>
- [5] Shields CL, Shields JA. Conjunctival tumors in children. *Curr Opin Ophthalmol* 2007; 18 (5): 351-60. <https://doi.org/10.1097/ICU.0b013e32823ecfbb>
- [6] Shields CL, Regillo AC, Mellen PL, Kaliki S, Lally SE, Shields JA. Giant conjunctival nevus: clinical features and natural course in 32 cases. *JAMA Ophthalmol* 2013; 131 (7): 857-63. <https://www.ncbi.nlm.nih.gov/pubmed/23702735>
- [7] Carol L. Shields; Airey Fasiuddin; Arman Mashayekhi; Jerry A. Shields. Conjunctival Nevi Clinical Features and Natural Course in 410 Consecutive Patients. *Arch Ophthalmol*. 2004; 122: 167-175.
- [8] Vizvári E, Skribek Á, Polgár N, Vörös A, Sziklai P, Tóth-Molnár E (2018) Conjunctival melanocytic naevus: Diagnostic value of anterior segment optical coherence tomography and ultrasound biomicroscopy. *PLoS ONE* 13 (2): e0192908. <https://doi.org/10.1371/journal.pone.0192908>
- [9] Deepali Jain. Pathological case of the month. Balloon cell nevus of the conjunctiva. *Arch Pediatr Adolesc Med*. 2001 Jan; 155 (1): 93-4. <http://www.pathologyoutlines.com/topic/eyenevi.html>
- [10] Carol L. Shields, Airey Fasiuddin, Arman Mashayekhi, Jerry A. Shields. Conjunctival Nevi. *Arch Ophthalmol*. 2004; 122: 167-175. <https://jamanetwork.com/journals/jamaophthalmology/fullarticle/416115>
- [11] Tobias Röck, Hans-Christian Bösmüller, Karl Ulrich Bartz-Schmidt, and Daniel Röck. Surgical management of a conjunctival nevus with amniotic membrane transplantation. *Int Med Case Rep J*. 2018; 11: 161–165. doi: 10.2147/IMCRJ.S164099.
- [12] Soltani-Arabshahi R, Sweeney C, Jones B, Florell SR, Hu N, Gross-man D. Predictive value of biopsy specimens suspicious for melanoma: support for 6-mm criterion in the ABCD rule. *J Am Acad Dermatol*. 2015; 72 (3): 412–418. doi: 10.1016/j.jaad.2014.11.030. <https://www.ncbi.nlm.nih.gov/pubmed/25582536>
- [13] Ji-Won Kwon. Laser Treatment of Conjunctival Nevus. *J Clin Ophthalmol. Eye Disord*. 2017; 1 (4): 1016. http://www.remedypublications.com/clinical-ophthalmology-eye-disorders/articles/pdfs_folder/jcoed-v1-id1016.pdf
- [14] Abdulrahman M. Alsharif, Saeed M. Al-Ghedan, Tariq Alasbali, Hisham S. Alkuraya, Nancy M. Lotfy, and Rajiv Khandekar. Argon Laser Photoablation for Treating Benign Pigmented Conjunctival Nevi. *Middle East Afr J Ophthalmol*. 2016 Jul-Sep; 23 (3): 247–249. doi: 10.4103/0974-9233.186098. <http://www.meajo.org/article.asp?issn=0974-9233; year=2016; volume=23; issue=3; spage=247; epage=249; aulast=Alsharif>