



Case Report

Endogenous Endophthalmitis by *Candida Albicans* Associated with a Primary Immunodeficiency Due to CARD9 Deficiency

Juliana Albano de Guimarães^{1,*}, Maria Campos Pires², Camillo Carneiro Gusmão¹,
Andrea Mara Simões Torigoe¹

¹Department of Ophthalmology, University of Campinas, Campinas, Brazil

²Faculty of Medicine, University of Itaúna, Itaúna, Brazil

Email address:

julianaalbanog@gmail.com (J. A. de Guimarães), mariacampospires@gmail.com (M. C. Pires), camillogusmao@gmail.com (C. C. Gusmão), andreatorigoe@gmail.com (A. M. S. Torigoe)

*Corresponding author

To cite this article:

Juliana Albano de Guimarães, Maria Campos Pires, Camillo Carneiro Gusmão, Andrea Mara Simões Torigoe. Endogenous Endophthalmitis by *Candida Albicans* Associated with a Primary Immunodeficiency Due to CARD9 Deficiency. *International Journal of Ophthalmology & Visual Science*. Vol. 4, No. 4, 2019, pp. 71-76. doi: 10.11648/j.ijovs.20190404.13

Received: September 1, 2019; **Accepted:** October 4, 2019; **Published:** October 15, 2019

Abstract: This report encompasses a case of endogenous endophthalmitis by *Candida albicans* in an otherwise healthy young adult patient, which led to the diagnosis of a primary immunodeficiency, CARD9 deficiency, associated with familial candidiasis. A 31-year-old female patient with a one-month history of low visual acuity (VA) in the right eye (RE) was referred after no response to treatment of toxoplasmosis and acute retinal necrosis. She presented no comorbidities, but a history of recurrent paronychia, oral candidiasis and *tinea capitis* since childhood. Her parents were first-degree cousins. Visual acuity was 20/2000 in the RE and 20/20 in the left eye (LE). There was an elevated exudative lesion occupying the retinal posterior pole, associated with fluffy white cotton balls in the adjacent posterior vitreous. Optical coherence tomography (OCT) showed macular lesions with the "rain cloud" sign. Fungal endogenous endophthalmitis was hypothesized. Imaging and laboratory examinations discarded other infections and eliminated involvement of other organs. Diagnostic vitreous puncture was performed in addition to Amphotericin B injection and intravenous Fluconazole. As culture results were negative, a vitreous biopsy was performed, in which *Candida albicans* was grown, followed by a second Amphotericin B injection. As there was no improvement, pars plana posterior vitrectomy, with placement of silicone oil, was performed. In spite of infection control, VA remained 20/2000. Due to a severe ocular condition with no other invasive sites of infection, associated with superficial recurrent fungal infections, a primary fungal specific immunodeficiency was suspected, resulting in referral to Immunology. An immunogenetic panel was performed, demonstrating heterozygosity for two CARD9 gene mutations, a molecule related to familial candidiasis. Follow-up in Ophthalmology and Immunology was maintained and oral Fluconazole was proposed to be taken for at least 6 months. Three months later, she presented with an oral abscess secondary to *Candida*, managed by the Otorhinolaryngology team. Fungal endogenous endophthalmitis is an important cause of morbidity and low visual acuity, especially in the population of immunocompromised patients. Early ophthalmological diagnosis should preferably be performed in order to prevent lesions from increasing, affecting noble areas such as the macula, and reaching the vitreous. When the fundus exam presents signs of fungal endophthalmitis in immunocompetent, young and healthy patients, diagnosis of primary immunodeficiencies should be considered.

Keywords: Endogenous Endophthalmitis, *Candida albicans* Endophthalmitis, CARD9 Deficiency, Familial Candidiasis

1. Introduction

Candida endophthalmitis is one of the main etiologies of endogenous endophthalmitis, usually occurring in immunocompromised patients, with baseline conditions such as decompensated diabetes mellitus, malignancies, use of chemotherapeutics, or hospitalization in intensive care units. In general, the condition is associated with the presence of foci of deep infection, such as abscesses, catheter infection and septicemia [1-4].

The genus *Candida* consists of non-filamentous fungi, *C. albicans* being the main pathogenic species in humans [5]. We report a case of endophthalmitis by *Candida albicans* in a young patient without comorbidities and in good general condition, as the initial presentation of a non-previously identified primary immunodeficiency. The deficiency of CARD9, a host innate immune signaling protein, essential for pattern-recognition of *Candida* antigens, is known to be related to a familial predisposition to *Candida* infections [6, 7]. According to the literature, this is the third reported case of *Candida* endophthalmitis associated with CARD9 deficiency [8, 9].

2. Case Report

A 31-year-old female patient, healthy, without known comorbidities, was referred with a complaint of progressive low visual acuity (VA) for 30 days in the right eye (RE), preceded by floaters. Outpatient treatment for toxoplasmosis

with sulfamethoxazole-trimethoprim and inpatient intravenous administration of Acyclovir for acute retinal necrosis were attempted previously in another service, without response.

On examination, VA was 20/2000 in RE and 20/20 in the left eye (LE), on the Snellen chart. There were no signs of inflammation in the anterior segment and intraocular pressure was normal in both eyes (BE). On fundus examination of the RE, there was evidence of vitritis and exudative chorioretinal lesions in the posterior pole, extending towards the vitreous cavity, with the presence of adjacent fluffy vitreous whitish balls in an aspect suggestive of "string of pearls". There were no abnormalities in LE fundus (Figure 1). Paronychia in the right thumb and non-painful whitish lesions in the oral cavity were noticed.

Recurrent fungal infections since childhood, such as paronychia, *Tinea Corporis*, *Tinea Capitis* and oral candidiasis were reported, never requiring hospitalization. Her parents were first cousins.

Fluorescein Angiography was performed; however, there were limited additional findings in relation to fundus examination due to blocked fluorescence areas, secondary to vitreous extension of the lesions. The ocular ultrasonography did not show any presence of choroidal abscesses or retinal detachment. Optical coherence tomography (OCT) obtained images at the edge of the lesions with a sign known as "rain cloud", characterized by a region of hyperreflectivity of internal layers of the retina in association with shadowing of external layers (Figure 2).

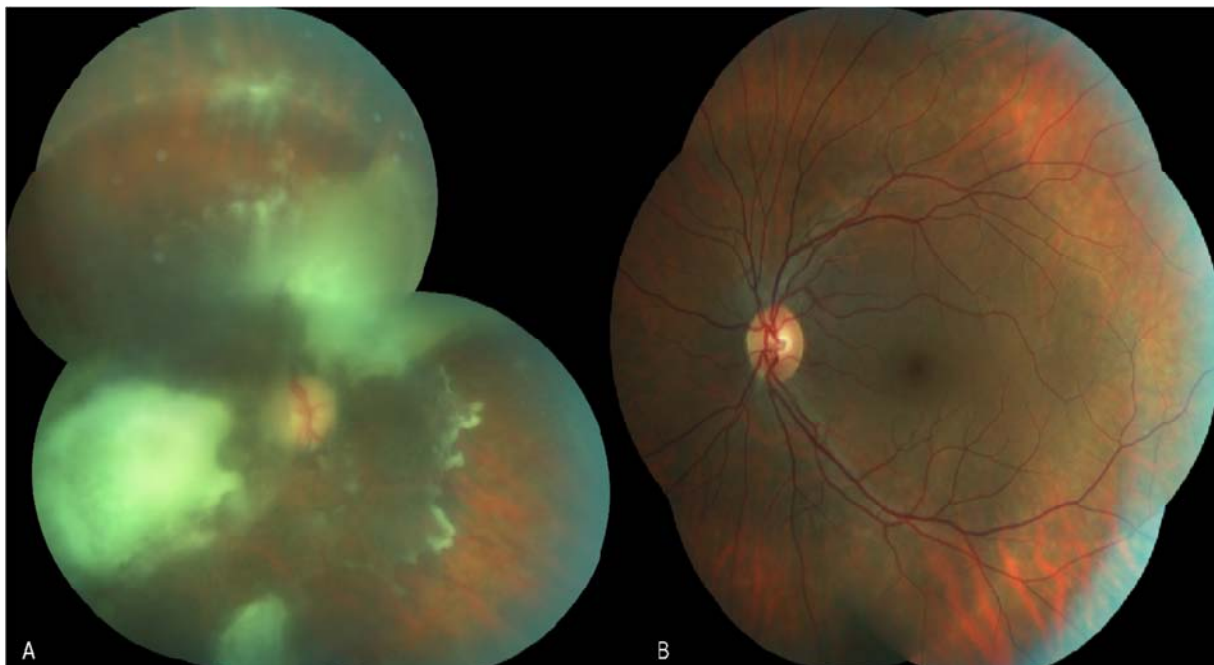


Figure 1. Fundus imaging of right (a) and left eyes (b).

In view of the fundus appearance of the eye and this specific signal in OCT, the hypothesis of fungal endophthalmitis secondary to *Candida* was raised, despite the good general condition and absence of known comorbidities of the patient.

Laboratory tests and imaging were performed to rule out other

hypotheses: a complete blood count without alterations, non-reactive HIV, negative serologies for toxoplasmosis, negative VDRL and FTA-abs, negative antinuclear factor (ANF), negative rheumatoid factor, C-reactive protein, erythrocyte sedimentation rate and blood glucose within the reference values.

Possible deep foci and complications were discarded with contrast tomography of the skull, orbits, chest and abdomen without alterations, negative blood cultures, echocardiogram without signs of valvular dysfunction or presence of vegetations, and preserved renal and hepatic functions.

Hospitalization for administration of intravenous Fluconazole, 400mg 12 / 12h, and planning of ophthalmological surgical approach followed. A vitreous puncture was initially performed, followed by intravitreal injection of amphotericin B 0.005mg / 0.1mL. The cultures

were negative and no improvement was observed. Therefore, a vitreous biopsy with a new injection of Amphotericin B was performed. A culture positive for *Candida albicans*, sensitive to usual antifungals, was obtained, but RE fundus remained unchanged. Thus, the patient underwent posterior vitrectomy via *pars plana* with the introduction of silicone oil. The procedure was performed without interurrences, but it was not possible to remove the whole posterior hyaloid, that was adhered to the lesions and to the posterior pole, with the retina presenting an already necrotic aspect (Figure 3).

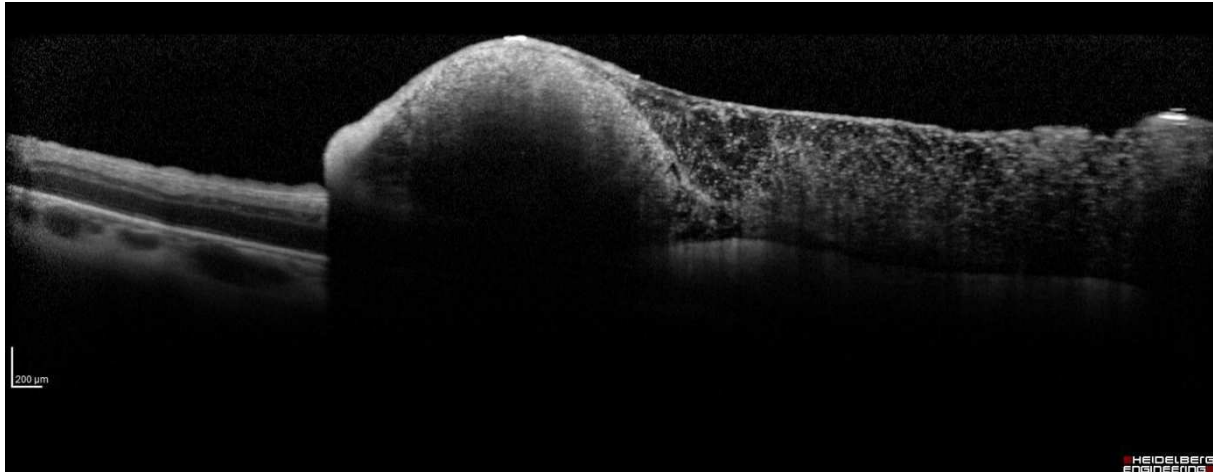


Figure 2. Rain cloud sign in OCT.

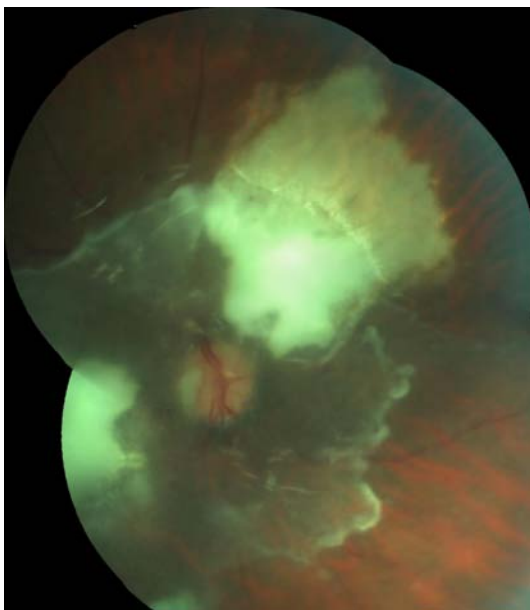


Figure 3. Fundus imaging after posterior vitrectomy.

The infection was considered controlled, although not cured, and the patient was discharged with oral Fluconazole, 400 mg / day. The final VA remained 20/2000, due to the location of the lesions, and the OCT continued to present the "rain cloud" sign on the edges of the unremoved hyaloid. Considering the good general condition of the patient, the presence of recurrent superficial fungal infections since childhood and the parents kinship, the hypothesis of a possible primary

immunodeficiency was elaborated and followed by a referral for immunological evaluation. The main suspected hypothesis would be the deficiency of CARD9, a rare autosomal recessive condition, associated with familial candidiasis.

Immunogenetic panel demonstrated heterozygosity for two CARD9 gene mutations. The variants found were: c.856C> T, considered pathogenic in relation to susceptibility to *Candida* infections, in which a glutamine amino acid is replaced at position 289 by a stop codon, early in protein translation, with probable destruction of messenger RNA via Nonsense-Mediated mRNA Decay (NMD); and c.1144C> T, in which there is a replacement of an amino acid arginine for cysteine at position 382, considered of undetermined clinical significance.

Follow-up in Ophthalmology and Immunology was maintained, as was continuous prophylaxis with oral Fluconazole. Three months later, referral to Otolaryngology was needed due to a toothache, which was found to be caused by a small abscess probably secondary to *Candida*, encountered by Nuclear Magnetic Resonance. The abscess was drained successfully and the patient kept monitoring in the three specialties.

3. Discussion

Endogenous or metastatic endophthalmitis, less common (2-8% of cases) than exogenous endophthalmitis, occurs due to hematogenous dissemination of microorganisms, with ocular penetration through the blood-retinal barrier. Fungi are responsible for 50 to 68.7% of cases of endogenous

endophthalmitis, composing an important etiology along with bacterial infections. *Candida* is the most common fungal genus to cause endogenous endophthalmitis, being *Candida albicans* the most prevalent species [1-3].

Candida albicans is a non-filamentous fungus that resides on human cutaneo-mucosal surfaces as a commensal microorganism. In conditions of immunocompetence, it rarely causes pathologies, which are mostly superficial conditions, such as mucovaginal candidiasis, paronychia and oral candidiasis. Otherwise, under conditions of Immune system impairment, *Candida albicans* can cause a multitude of diseases, from chronic mucocutaneous candidiasis (CMC), characterized by recurrent superficial infections in skin, hair and mucous membranes, to invasive infections such as esophageal candidiasis, endocarditis, hepatic abscesses, candidemia and endophthalmitis [3]. In general, *Candida* endophthalmitis occurs in patients with candidemia or disseminated fungal infection, with an incidence of 9 to 45% in these cases, a number that has reduced with the advent of prophylaxis and early treatment [3, 10].

Risk factors associated with candidemia and consequently, *Candida* endophthalmitis include neutropenia, uncontrolled diabetes mellitus, malignancies, chemotherapy, long-term use of broad-spectrum antibiotic therapy and long-lasting venous catheters. The presence of superficial candidiasis is not considered a risk factor for the occurrence of intraocular infections [4]. Cases of *Candida* Endophthalmitis without the presence of risk factors have already been reported by *Chavan et al* and *Yeşiltaş et al*, in which Paronychia and Onychomycosis of lower limb nails were the focus of infection, respectively [11, 12]. In the case reported, the diagnostic difficulty was due to the fact that, despite the typical fundus lesion, the patient did not have any known risk factors to raise the diagnostic suspicion.

Genetically inherited conditions that result in immunity disorders associated with *Candida* infections generally involve the innate immunity, which is characterized by the recognition of genetically predetermined patterns, culminating in activation of defense mechanisms. The caspase recruiter domain 9 (CARD9) is a protein selectively produced in cells of the myeloid lineage, critical in the signaling cascade initiated by pattern recognizing receptors associated with innate immunity against fungi. The biallelic deficiency of the locus responsible for the transcription of CARD9 protein is therefore an autosomal recessive disorder associated with a predisposition to fungal infections [6, 7]. One of the alleles found in the immunogenetic study of the patient was previously known as pathological, while the other has still no recognized clinical significance. Considering the patient's history and clinic, this allele might be possibly related to a loss of function of the translated protein.

Two reports of *Candida* endophthalmitis associated with CARD9 deficiency are found in the literature: one reported by *Jones et al.* [8] and the other by *Gavino et al.* [9], both in female patients without comorbidities, with CARD9 deficiency, and with manifestation in adulthood. Other manifestations of immunodeficiency were osteomyelitis in the

first case and cerebral abscesses in the second one.

Patients with *Candida* endophthalmitis usually present with a subacute onset of floaters and visual blurring, which may be associated with ocular discomfort and photophobia. Peripheral chorioretinal lesions may initially be asymptomatic. Ciliary injection and chamber reaction, with or without hypopyon, may be present. The most characteristic lesion of endophthalmitis by *Candida* is the whitish chorioretinal lesion of cottony appearance. These lesions may be single or multiple, unilateral or bilateral and, as they progress, extend into the vitreous cavity. Small vitreous abscesses appear as "fluffy cotton balls" which generate the appearance of a "string of pearls" when lined up. The vitreous involvement usually indicates poor prognosis due to penetration of the pathogen through Bruch's membrane into the intraocular environment, protected from the reach of antifungal agents by the blood-retinal barrier. Other non-specific lesions include intraretinal hemorrhages, areas of retinal necrosis, Roth spots, and retinal vascular occlusions [4]. Imaging tests are ultrasonography (USG), fluorescein angiography (AFG) and optical coherence tomography (OCT). In the USG, choroidal abscesses, vitreous cellularity, choroidal thickening and retinal detachment can be evidenced. AFG may demonstrate hyperfluorescence, indicative of lesion activity. The OCT shows, during periods of activity, retinal or chorioretinal lesions. The first are lesions confined to the internal layers of the retina, with a rounded shape. The latter, which were present in the reported case, are elevated and hyperreflective lesions at the vitreoretinal interface, with obscuration of underlying retinal layers due to shade, the "rain cloud" sign, and discontinuation of RPE. Vitreous cellularity and thickening of posterior hyaloid can be verified. As the condition improves, the lesion is progressively flattened and the architecture of the inner layers is progressively restored, unlike the outer layers, which remain with discontinuity and atrophy, revealing hyperreflectivity of the subretinal scar [13, 14].

In cases suggestive of candidemia, positive culture of probable foci, such as long-lasting catheters, urine, blood or other secretions, strengthens the presumptive diagnosis. Blood cultures, however, are only positive in about 50 to 75% of cases of endophthalmitis, probably due to transient candidemia [15, 16]. Regarding *Candida* identification in vitreous material, it is believed that the sensitivity of culture in vitreous biopsy material is higher than in fine needle puncture material (17), as reflected in the reported case, most likely due to the highest concentration of the pathogen being near the retina, a place of difficult access during the puncture. Furthermore, molecular tests such as polymerase chain reaction (PCR) were shown to be the most advantageous method, due to their higher sensitivity, higher speed, and the need for smaller sample volumes [15].

Treatment should begin as soon as the diagnosis is suspected to ensure the best possible prognosis. In addition to systemic antifungal agents, intravitreal antifungal drugs are necessary in order to overcome the blood-retinal barrier. There are different antifungal options for intravitreal injection and

Amphotericin B is still preferred. The use of intravitreal steroids remains a controversial subject, and there is no controlled clinical trial proving benefits. The surgical approach is the hygienic vitrectomy, indicated in cases of extensive vitreous involvement or absence of improvement. Early surgery may be indicated in cases of foveal involvement or in cases of initial presentation with low visual acuity. The vitrectomy has diagnostic and therapeutic utility, through removal of fungal load and laboratory analysis of the material. Benefits of surgery include prevention of epiretinal membrane formation and occurrence of tractional retinal detachment through vitreous contracture [4, 17, 18].

Regarding the primary immunodeficiency caused by the CARD9 gene mutation, the only definitive treatment consists of transplantation of hematopoietic cells, as the individual's neutrophils do not recognize and, consequently, combat *Candida* species (6). Further treatment attempts are underway, such as the subcutaneous introduction of macrophage-granulocyte colony stimulating factors (GM-CSF) [7]. In the reported case, Immunology proposal was to keep Fluconazole for six months, with extension or alteration of the treatment in case of recurrence of *Candida* activity, in the eyes, teeth or other organs.

The visual prognosis depends on several factors. These include virulence of the pathogen, location of the lesion (foveal lesions have worse prognosis), timing of the approach (the earlier the better) and the presence of complications such as retinal detachment, formation of epiretinal membranes and development of choroidal neovascularization [4]. In general, patients who underwent injection of antifungal agents and vitrectomy present better final visual acuity than patients who did not receive this type of treatment [17]. The patient's prognosis is also closely related to the severity of the systemic condition. In the case of the presented patient, the visual prognosis was low due to pathogen load, foveal involvement and late diagnosis.

4. Conclusion

The aims of this case report are, firstly, to emphasize that *Candida* endophthalmitis is not only seen in patients with known risk factors for this condition and, secondly, to draw attention to rare genetic conditions such as CARD9 deficiency. High index of suspicion should exist in cases suggestive of *Candida* endophthalmitis, even in the absence of identifiable risk factors, so that the visual results are favorable. Diagnosing and following patients with immunodeficiencies like the one described result in a better prognosis for the patient, not only in the field of Ophthalmology, but also in terms of preventing other infections and manifestations.

References

- [1] Son HJ, Kim MJ, Lee S, Choi S, Jung KH, Jung J, Chong YP, Kim SH, Choi SH, Kim WS, Woo JH, Lee JY, Lee SO. Risk factors and outcomes of patients with ocular involvement of candidemia. *Plos One*. Vol. 14, No. 9, 2019, e0222356.
- [2] Coneell PP, O'Neill EC, Fabinyi D, Islam FMA, BATTERY R, McCombe M, Essex RW, Roufai E, Clark B, Chiu D, Campbell W, Allen P. Endogenous endophthalmitis: 10-year experience at a tertiary referral centre. *Eye*. Vol. 25, 2011, pp. 66-72.
- [3] Chhablani J. Fungal endophthalmitis. *Expert Rev. Anti Infect. Ther.* Vol. 9, No. 12, 2011, pp. 1191-1201.
- [4] Sallam A, Lynn W, McCluskey P, Lightman S. Endogenous *Candida* endophthalmitis. *Expert Rev. Anti Infect. Ther.* Vol. 4, No. 4, 2006, pp. 675-685.
- [5] Ueda T, Takesue Y, Tokimatsu I, Miyazaki T, Nakada-Motokawa N, Nagao M, Nakajima K, Mikamo H, Yamagishi Y, Kasahara K, Yoshihara S, Ukimura A, Yoshida K, Yoshinaga N, Izumi M, Takeya H, Yamada K, Kawamura H, Endou K, Yamanaka K, Yoshioka M, Amino K, Ikeuchi H, Uchino M, Miyazaki Y. The incidence of endophthalmitis or macular involvement and the necessity of a routine ophthalmic examination in patients with candidemia. *Plos One*. Vol. 14, No. 5, 2019, e0216956.
- [6] Drewniak A, Gazendam RP, Tool AT, van Houdt M, Jansen MH, van Hamme JL, van Leeuwen EM, Roos D, Scalais E, de Beaufort C, Janssen H, van den Berg TK, Kuijpers TW. Invasive fungal infection and impaired neutrophil killing in human CARD9 deficiency. *Blood*. Vol. 121, No. 13, 2013, pp. 2385-2392.
- [7] Gavino C, Cotter A, Lichtenstein D, Lejtenyi D, Fortin C, Legault C, Alirezaie N, Majewski J, Sheppard DC, Behr MA, Foulkes WD, Vinh DC. CARD9 Deficiency and Spontaneous Central Nervous System Candidiasis: Complete Clinical Remission With GM-CSF Therapy. *Clinical Infectious Diseases*. Vol. 59, No. 1, 2014, pp. 81-84.
- [8] Jones N, Garcez T, Newman W, Denning D. Endogenous *Candida* endophthalmitis and osteomyelitis associated with CARD9 deficiency. *BMJ Case Rep*. Published online: 2016. Doi: 10.1136/bcr-2015-214117.
- [9] Gavino C, Mellinghoff S, Cornely OA, Landekic M, Le C, Langelier M, Golizeh M, Proske S, Vinh DC. Novel bi-allelic splice mutations in CARD9 causing adult-onset *Candida* endophthalmitis. *Mycoses*. Vol. 61, No. 1, 2018, pp. 61-65.
- [10] Feman SS, Nichols JC, Chung SM, Theobald TA. Endophthalmitis in patients with disseminated fungal disease. *Trans. Am. Ophthalmol. Soc.* Vol. 100, 2002, pp. 67-71.
- [11] Chavan R, Mustafa MZ, Narendran N, Tarin S, Yang Y. A case of *Candida albicans* endophthalmitis with no predisposing risk factors and a distant source of infection. *Case Rep. Ophthalmol.* Vol. 3, 2012, pp. 277-282.
- [12] Yeşiltaş YS, Özcan G, Demirel S, Yalçındağ N. Culture-Proven *Candida Albicans* Endogenous Endophthalmitis in a Patient with Onychomycosis. *Ocul Immunol Inflamm.* Vol. 22, 2019, pp 1-4.
- [13] Lavine JA, Mittelu M. Multimodal imaging of refractory *Candida* chorioretinitis progressing to endogenous endophthalmitis. *Journal of Ophthalmic Inflammation and Infection*. Vol. 5, No 24, 2015, pp. 1-5.
- [14] Invernizzi A, Symes R, Miserocchi E, Cozzi M, Cereda M, Fogliato G, Staurenghi G, Cimino L, McCluskey P. Spectral Domain Optical Coherence Tomography findings in endogenous *Candida* Endophthalmitis and their clinical relevance. *Retina*. Vol. 38, No. 5, 2018, pp. 1011-1018.

- [15] Lingappan A, Wykoff CC, Albin TA, Miller D, Pathengay A, Davis JL, Flynn Jr HW. Endogenous fungal endophthalmitis: causative organisms, management strategies, and visual acuity outcomes. *American journal of ophthalmology*. Vol. 153, No. 1, 2012, pp. 162-6.
- [16] Binder MI, Chua J, Kaiser PK, Procop GW, Isada CM. Endogenous endophthalmitis: an 18-year review of culture-positive cases at a tertiary care center. *Medicine (Baltimore)*. Vol. 82, No. 2, 2003, pp. 97-105.
- [17] Zhang YQ, Wang WJ. Treatment outcomes after pars plana vitrectomy for endogenous endophthalmitis. *Retina*. Vol. 25, No. 6, 2005; pp. 746-750.
- [18] Kernt M, Neubauer AS, Kaspar HM, Kampik A. Intravitreal Voriconazole: In Vitro Safety-Profile for Fungal Endophthalmitis. *Retina*. Vol. 29, No. 3, 2009, pp. 362-370.