

A New Test System and a New Cause for Acquired Foveal Color-Vision Deficiency

Terry Bahill

Systems and Biomedical Engineering, University of Arizona, Tucson Arizona, USA

Email address:

terry@sie.arizona.edu

To cite this article:

Terry Bahill. A New Test System and a New Cause for Acquired Foveal Color-vision Deficiency. *International Journal of Ophthalmology & Visual Science*. Vol. 1, No. 1, 2016, pp. 8-19. doi: 10.11648/j.ijovs.20160101.12

Received: August 22, 2016; **Accepted:** November 8, 2016; **Published:** December 2, 2016

Abstract: The purpose of this paper is to show a new cause of a macular scotoma and an anomalous acquired color-vision deficiency in the clinical fovea caused by retina detachments and subsequent surgeries. This deficiency was measured with a visual test system composed of multiple lasers, a white light beam and dozens of targets that were projected on a computer monitor and printed on paper. Lasers were used, because they produce small monochromatic target dots, 0.07 degrees of visual angle (6 mm) in diameter. The outputs of the system were the subject's perceived color matches. In experiments with small dots of laser light, colors were judged correctly by the right eye (OD); however, the left eye (OS) could not distinguish colors. For example, a green laser dot appeared green to his OD and white to his OS. Perceived color in the abnormal OS depended on the target's hue, saturation, luminance, wavelength, size and position on the fovea. This subject has an acquired color-vision deficiency in the clinical fovea of his OS. These visual anomalies are consistent with damage to retinal ganglion cells. Strangely, his OS does not see negative-color afterimages.

Keywords: Acquired Color-Vision Deficiency, Color Perception, Color Vision, Peeling Inner Limiting Membrane, Unilateral Dichromate

1. Introduction

Five percent of people are born colorblind (color-vision deficient) [1, 2]. Another ten percent acquire color-vision deficiency by middle age [3]. Common causes of color-vision deficiency include cataracts, high blood pressure, corneal edema, wet and dry age-related macular degeneration, diabetic retinopathy, migraine headaches, optic neuritis, multiple sclerosis, cerebral achromatopsia, glaucoma, aging, head injuries, accidents, strokes and medications [2]. The subject of this paper acquired color-vision deficiency, but not from any of these causes.

Due to complications during cataract removal surgery and subsequent detached retinas, the subject of this paper, the author, has had a dozen eye operations. He has been examined and treated by an optometrist and eleven ophthalmologists Bahill and Barry [4, 5]. These surgeries and procedures had unintended consequences, including a scotoma in the left macula and an acquired color-vision deficiency in the left fovea, these are the main topics of this paper.

A scotoma in the lower-left octant of his field of view

started after the inner limiting membrane (ILM) was peeled off in an effort to reduce cystoid macular edema, after one of the detached retina operations. Peeling of the ILM is known to reduce visual acuity and produce scotomas.

Tadayoni et al. [6] wrote "ILM peeling may reduce retinal sensitivity, and significantly increase the incidence of microscotomas.... We found that mean retinal sensitivity was significantly lower ... in eyes that underwent peeling than in those that did not. Postoperative microscotomas were also significantly more frequent in eyes that had undergone peeling.... mean macular sensitivity was found to be lower by about 3.4 dB in eyes with ILM peeling ... after ILM peeling, the retina needed more than twice as much light to see the spot as before peeling." In investigating the cause of damage they wrote, "The cause of the development of microscotomas after peeling has still not been established. [Possibilities include] ... direct trauma caused by the forceps when gripping the ILM ... disruption of the inner/outer photoreceptor segment junction ... dyes ... have a toxic effect on ganglion cells ... deterioration of the retina, especially of the Müller cells.... Deterioration of other cells ... due to the stretching caused by the peeling, or

indirectly, due to Müller cell deterioration.”

The adverse effect of peeling the ILM on color vision is less well documented. However, Poon et al. [7] “suggest that chromatic contrast thresholds, especially the red-green contrast threshold, represent a better prognostic guide for visual improvement after macular hole surgery than VA [visual acuity] measurement.”

A detached retina could disturb the photoreceptor layer. In particular, macular retinal detachment could harm S-cones. Such patients would show a blue-yellow (tritan-like) color discrimination deficit [8, 9]. The fragile S-cones might be more susceptible to stress than the M-cones or L-cones [10].

A dozen eye surgeries on this patient had several unintended consequences including (1) pain caused by the haptics of the intraocular lens (IOL) damaging the iris, (2) a resulting frozen pupil that does not respond to light or drugs, (3) strabismus (including excyclorotation) caused by the scleral buckle damaging or interfering with the superior rectus and superior oblique muscles, (4) a wrinkled retina caused by the macula-off detached retina, (5) headaches caused by a continual retinal induced asthenopia due to the

excyclorotation and the wrinkled retina, (6) lack of stereopsis and presence of amblyopia due to the diplopia, (7) an absolute macular scotoma (blind spot) and (8) an acquired color-vision deficiency [4,5]. Effects of the wrinkled retina and the macular scotoma are shown in Fig. 1.

Creating Fig. 1 was complex and time consuming. For this subject, the luminance threshold for the left eye (OS) is about a log unit higher than for the right eye (OD). Therefore, a log unit neutral density filter was put on the spectacle lens for the OD. A black and white paper target was displayed 2.9 m away from the eyes, so that 5 cm on the target equaled one degree on the retina. In our first technique for testing acuity, the *alternating* views technique, the subject fixated on the center of the target and perceived a small portion of the target with foveal or off-foveal vision. Then he sketched that small portion of Fig. 1. He did this alternately with the left and right eyes. This process was repeated dozens of times. Then months later, the process was repeated, etc. No changes in Fig. 1 were noted over the last eight years.

2. Materials and Methods

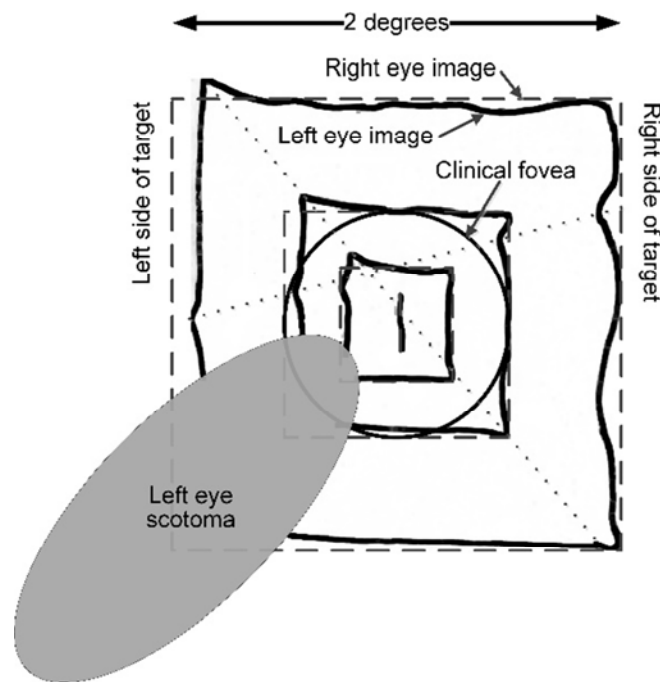


Figure 1. The left eye's vision is distorted. The subject was looking at a small black-line target composed of concentric squares. The right eye's image (thin dashed lines) is the same as the visual target. The left eye's image (thick solid lines) shows distortion due to a wrinkled retina and an absolute scotoma (gray oval).

2.1. Techniques and Targets

Our second technique used *simultaneous* viewing with both eyes. The subject has strabismus, because of the scleral buckle implanted during his first detached retina operation. Therefore, during relaxation of the eyes, closure of the eyelids or covering of the OS, the OS drifts left and if there is an image on the OS, then it drifts to the right. Therefore, with this technique, the subject allowed his eyes to diverge so that his OD saw the target in its normal position and simultaneously his OS saw the target

image that had drifted to the right. He then adjusted the sketch of Fig. 1. These two techniques will be discussed again in section 3.3. These techniques produced the same sketch for Fig. 1. This figure is the result of many measurements taken over several years. Nevertheless, it was worth the effort, because no clinical ophthalmologic instrument gave resolution this fine. Figure 1 is black and white, like the results of typical visual fields tests. Both use achromatic targets and displays.

The subject is colorblind in the OS. No existing ophthalmological instruments were able to measure, document

and explain this acquired color-vision deficiency. Therefore, a new color-vision test system was developed. Unlike existing color-vision deficiency tests, it was *not* designed to detect color-vision deficiency caused by (1) genetic rod and cone photoreceptor biochemical deficiencies or (2) lesions in the cortex. It was designed to detect monocular acquired color perception deficiencies in the fovea.

This system uses four types of visual targets: laser beams, images displayed on computer monitors, images displayed on paper and afterimages. The system comprises four lasers, a focused white light beam and dozens of targets displayed on computer monitors and printed on paper. The protocol is similar to a Humphrey visual fields test, except that most of its patterns are displayed within the clinical fovea, the central one-degree disk of the visual field.

The primary visual targets for these experiments were four laser dots of light with the following color names and wavelengths: red 635 nm, yellow 593 nm, green 532 nm and blue 447 nm. Because these light sources were monochromatic lasers, the saturation was 100%. The lasers could not be replaced with light emitting diodes (LEDs), because LEDs are not 100% saturated. The right column of Fig. 2, which will be presented later, shows the color of these dots of light: however, this is only an approximation, because whatever you are reading this paper with, whether it be printed pages or a computer monitor, its color images cannot be 100% saturated. The laser beams were projected onto a sheet of glossy white photo paper 5.25 meters from the subject: at this distance, the dots were 0.07 degrees (6 mm or 4 min of arc) in diameter. This is smaller than a letter on the 20/20 line of a Snellen chart, which is 8 mm. The lasers were class IIIa and IIIb with various attenuating filters. The lasers were clamped in vices. When they had to be hand-held, they were held in contact with skull bones to reduce vibrations.

Targets displayed on the computer monitor were created with Visio software. The computer monitor was a 24-inch LCD

Samsung SyncMaster 245BW. For all targets and experiments, the output of the system was the subject's perceived color derived by adjusting the red, green and blue (RGB) values and the hue, saturation and luminance (HSL) values to make the adjustable-color object match the fixed-color target. The subject used both RGB and HSL values to match colors. However, he found it easier to match colors with HSL. {This technique is described later with Fig. 5.}

The subject, a 67 year old male, was dark adapted and wore spectacles that gave best corrected Snellen chart visual acuity of 20/20 for the OD and around 20/50 for the OS. For the laser targets, the viewing was monocular in a dimly lit laboratory. In addition to the scotoma in the superior-nasal octant of the clinical macula of his left-eye (shown in the lower-left octant of Fig. 1), the subject is also color-vision deficient in the clinical fovea of the left-eye. This work was carried out in accordance with the Code of Ethics of the World Medical Association (Declaration of Helsinki). The subject is the author.

2.2. Nomenclature

When referring to a region of a photograph or a diagram, geometric descriptions will be used, for example the *lower-left* octant of Fig. 1. In contrast, when referring to anatomy, anatomical descriptions will be used, for example, the scotoma in the *superior-nasal* octant of the clinical macula.

Clinicians use the term *fovea* to name the 1° diameter disk at the center of the retina and they use the term *macula* to name the 5° diameter disk surrounding it. On the other hand, anatomists and histologists use the term *fovea* to name the 5° diameter disk at the center of the retina and they use the term *macula* to name the 20° diameter disk surrounding it. In this paper, when referring to regions of the retina, clinical definitions as given in Table 1 will be used.

Table 1. Names for regions of the retina from [5].

Description	Approximate diameter on retina	Clinical or Classic name (s)	Anatomical name (s)	Characteristics	Size comparison For a man with his arm extended in front of him it is approximately [15]...
Center of foveal pit	0 mm, 0°	Center of fovea	Umbo	It is the center of the fovea.	
Floor of foveal pit	0.3 mm, 1°	Fovea, fovea centralis	Foveola	It is the area of highest visual acuity. It has no rods or vasculature. It has no S cones in the central 0.35° disk.	the width of the fingernail on the little finger
Capillary free zone	0.6 mm, 2°	Foveal avascular zone	Foveal avascular zone	It has no arterioles or venules. It is not circular.	the width of the index finger at the proximal interphalangeal knuckle
Sloping sides of the foveal pit	1.4 mm, 5°	Macula, macula lutea	Fovea, fovea centralis	It is the darkly pigmented <i>disk</i> in the center of the retina. It has no rods, only cones.	the distance between this proximal interphalangeal knuckle and the tip of the index finger
Rim of the foveal pit	1.9 mm, 6.5°	Rim of the foveal pit	Rim of the foveal pit	It is the thickest part of the retina. It is about the size of the optic disk.	
Ring around the foveal pit	2.9 mm, 10°		Parafovea	Its ganglion cell layer has four to six rows of cells.	the width of the fist
Ring around parafovea	5.7 mm, 20°		Perifovea	Its ganglion cell layer has two or three rows of cells.	
Disk comprised of all the above	5.7 mm, 20°	Posterior pole	Macula, area centralis	Its ganglion cell layer has multiple rows of cells: outside of this disk, there is only one row.	the width of two fists

For comparison, the optic disk is about 6.3° in diameter and the sun and the moon are ½° in diameter. One millimeter in the macula of an emmetropic human adult corresponds to 3.5° of visual angle (0.287 mm/degree) with a variance around 3%.

3. Results

3.1. Color-Vision Deficiency

If the main object in the subject's visual field was a small green dot of light, then it appeared green to his OD and white to his OS. This was repeatable, initially in intraocular pressure tests with the green LED fixation target of the Reichert AT555 non-contact tonometer and the ZEISS VISUCAM^{®PRO NM} fundus camera (these fixation points were estimated to be 2 mm in diameter) and later with lasers in the laboratory.

3.1.1. Standard Color-Vision Deficiency Tests

An optometrist and an ophthalmologist wrote in their referral reports that the subject passed the Ishihara tests of color vision. However, in the laboratory when the targets of the Ishihara, Hardy-Rand-Rittler and Farnsworth-Munsell color-vision tests were reduced in size so that they filled a little more than the clinical fovea, when using the left eye our

subject failed all three of the tests. This shows the importance of target size. Historically, this was not important, because genetic abnormalities affect all regions of the retina. However, our test system is specific for small-area defects in the clinical fovea.

For the Ishihara tests for color-blindness, the distance from the computer monitor was adjusted so that the test plates had varying diameters. Viewing was monocular. With his OD, the subject perceived all of the Ishihara test plates correctly. With his OS, the subject's performance depended on the visual angle subtended by the plates. At two degrees, the only plates he identified correctly were the plates that had no numbers or lines and he stated that he saw no numbers or lines. If the plates were reduced to one degree of visual angle, then even the OD could not resolve the small dots. The plates were taken from these web sites:

<http://www.color-blindness.com/ishihara-38-plates-cvd-test/#prettyPhoto>

Table 2. Results of Ishihara color-vision deficiency tests with 8 cm plates.

Distance from image to eye	Visual angle of plate	OS Percent correct	Suggestion
28 cm	16°	89%	No color-vision deficiency
57.3 cm	8°	53 %	Weak to moderate red-green color-vision deficiency
115 cm	4°	43%	Moderate red-green color-vision deficiency
230 cm	2°	10%, these were the control plates where there was no pattern and the OS saw no pattern	Strong red-green color-vision deficiency

The instructions for the Hardy-Rand-Rittler (HRR) pseudoisochromatic plates say that they should be viewed binocularly from a distance of 40 cm [11]. The plates are 13.3 cm (500 pixels) on a side. Therefore, the plates should cover 18 degrees of the visual field. With these instructions, the OS saw eight out of ten plates correctly, one plate partially and nothing on one plate. With monocular viewing of plates subtending two degrees of the visual field, the OS saw zero plates correctly.

For the X-Rite color IQ test (a simplified on-line version of a Farnsworth-Munsell 100 Hue Test), each test disk subtended 1.3 degrees when viewed from 57.3 cm. Viewing was monocular. His OD scored 16, which is low and therefore good: his OS scored $\bar{x} = 200$, $\sigma = 52$, $n = 5$, which is poor and in the 99th percentile.

http://xritephoto.com/ph_toolframe.aspx?action=coloriq.

The results of all three of these commercial color-vision deficiency tests were size dependent for the OS. If the targets were 10 to 20 degrees of visual angle (so that they engaged the periphery of the retina), then the OS usually guessed correctly.

Of course, a computer monitor cannot produce true colors. So an internet measurement cannot substitute for a comprehensive optometric or ophthalmological exam. However, in spite of the lack of a double-blind study with numerous subjects, it is safe to conclude that this subject is an unusual case of a monocular foveal color anomaly that is not based on genetic rod and cone photoreceptor biochemical deficiencies.

3.1.2. More Nomenclature

The terms that are traditionally used to describe a genetically colorblind person are not applicable to this subject. The condition of his OS is not deuteranopia, protanopia or tritanopia, because (for two-degree squares) he can distinguish red, green and blue. At first blush (because of Figs. 4 and 6, which will be presented later), we might think that the subject could be described as weakly-green-color-deficient, like a deuteranomalous person. However, that classification is wrong, because he can distinguish green and red. He is not deuteranomalous or protanomalous because (1) he can distinguish between red, orange, yellow and green, and (2) on the CIE chromaticity diagram, he can distinguish colors on the deuteranope and protanope confusion lines between the white point and saturated colors with wavelengths between 490 and 505 nm; he does not confuse these colors with white. His condition is not tritanomalous, because he can distinguish blue, green and red (although his reds and blues are darker and more unsaturated than normal). So, could he be a weak anomalous trichromat? Using Asada's convertor¹ we could say that his color vision matches (1) a

¹ Kazunori Asada's web site <http://asada.tukusi.ne.jp/> contains several color vision assist tools including Chromatic Glass, which "is a color vision assistance tool for persons who have difficulty recognizing specific colors or perceiving differences between specific color pairs due to a color-vision deficiency. Congenital color-vision deficiency can be classified into three major types: Protanope / Protanomalous, Deuteranope / Deuteranomalous and Tritanope / Tritanomalous."

person who is 75% or more tritanomalous except that his reds and blues are too dark, or (2) a person who is 25% or more protanomalous except that his reds are too dark, or (3) a person who is 25% or more deuteranomalous except that his reds are too dark and his greens are too pale. From all of this, it must be concluded that the terms used to describe congenitally colorblind people are not applicable to this subject, because these terms describe retinæ with deficiencies in a particular class of cones.

3.2. Experiments with Colored Lasers



Figure 2. The subject's color-vision deficiency depends on the wavelength (the hue) of the visual target. The left column shows the perceived colors of the four laser beams when they were shone on the target screen and viewed with the left eye. The right column shows the colors of the laser beams as perceived by the right eye (OD). The laser dots were 0.07 degrees in diameter. With monocular viewing, the OD judged the hues correctly, while the OS perceived a shift in hue, a reduction in saturation and a huge reduction luminance.

Figure 2 shows the results of the perceived-color experiments with laser beams. With monocular foveal left-eye viewing of the laser beams projected on white photo paper, the red laser dot (0.07 degrees in diameter) appeared pink; the green laser dot appeared white; the blue laser dot appeared pale blue; and the yellow laser dot appeared yellowish-white. The columns of Fig. 2 were produced with the OS looking at the laser dots and later the OD viewing equivalently sized dots on a computer monitor while adjusting the hue, saturation and luminance. As previously stated, the figures in this paper do not produce the true colors of the lasers, because neither the computer monitor nor the printed page can produce pure spectral colors like those that lasers do. Luminance changes of plus or minus one log unit had little effect on perceived color in either eye.

People with different types of color-vision deficiency perceive colors differently. The colors which can be recognized or distinguished by color deficient persons are different from color normal persons. In addition, such conditions may occur owing to an acquired illness. 'Chromatic Glass' helps users to recognize and distinguish such colors by making a special modified color image based on scientific theoretical methods in real-time and displaying it and the original image alternately." It is available for free at <http://asada.tukusi.ne.jp/chromaticglass/e/index.html>

This is a relative (not absolute) field defect, because removing the attenuating filter on the green laser increased its brightness by a factor of ten and made its dot larger. Subsequently, the green dot appeared pale bluish-green when viewed with the clinical fovea of the left eye.

Position on the retina obviously must have an effect on the subject's perceived color, because of (if nothing else) the scotoma in the macula of the OS shown in Figure 1. For all four lasers, the subject's OS saw nothing when the small laser dots of light were in the region of the scotoma, it saw white dots in most other areas of the clinical fovea and it saw unsaturated dots outside of the fovea, as shown in Fig. 3. Of the four lasers, the red dots were the most visible (brightest) to the OS, the green dots were the least visible (dimmiest) in the fovea and the yellow dots were the least visible (dimmiest) outside of the fovea. Therefore, this color-vision defect was not uniform across the retina or across wavelengths.

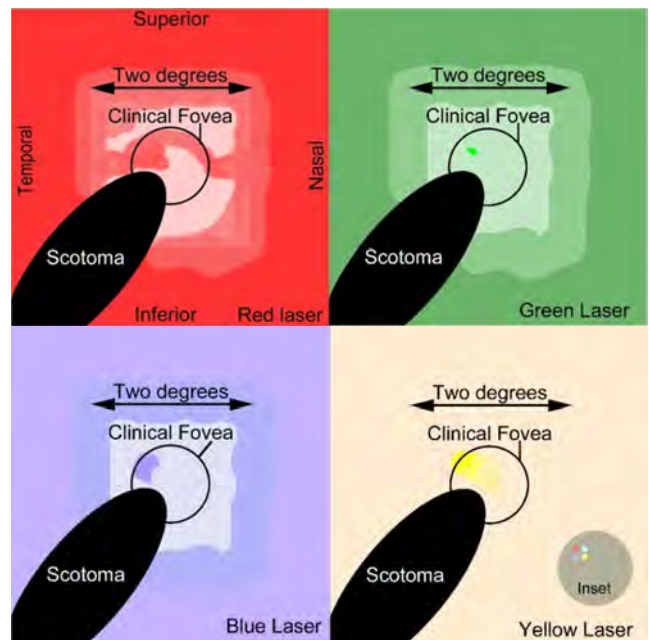


Figure 3. The color-vision deficiency depends on the position on the retina. The perceived color of the four laser dots changed as they excited different areas of the OS retina. The upper-left quadrant of the figure is for the red-laser dot. When it was viewed monocularly with the center of the clinical fovea, it appeared pink. When the red laser dot was positioned on the rest of the central two-degree square, it was rose colored. When it was positioned on the rest of the retina, it was unsaturated red. None of the laser dots was visible in the area of the macular scotoma (black oval). The upper-right quadrant of the figure shows that the green-laser dot appeared greenish-white when it was positioned on the OS clinical fovea. The lower-left quadrant shows some sensitivity to blue light in the fovea. The yellow laser was only visible in a small section of the fovea. The inset in the lower-right corner will be explained in the Discussion section.

The colored laser light beams added as expected. For example, when the red and green laser beams were superimposed, the resultant was perceived as yellow by the OD and as white by the OS: when the red and yellow lasers were superimposed, the resultant was perceived as orange by the OD and as white by the OS: when the red and blue lasers

were superimposed, the resultant was perceived as magenta by the OD and as brownish-white by the OS; and when the blue and green lasers were superimposed, the resultant was perceived as cyan by the OD and as white by the OS. To get these effects, the laser beams had to have nearly equal sizes and luminance.

These three laser beam effects are consistent with destruction of retinal ganglion cells. Although less likely, they could be consistent with the brain achromatically suppressing the OS vision, because of the OS excyclophoria, diplopia and the asthenopia.

3.3. Colors Displayed on a Monitor

The experiments with targets displayed on a computer monitor and the techniques that were used to match perceived colors will now be described. With the first technique, the fixed-color target squares (two degrees per side) shown in column 1 of Fig. 4 were displayed on a computer monitor with neutral colors in column 2. The subject covered his OD with his hand or a black patch and used his OS to look at one of the fixed-color target boxes in column 1. He fixed that color in his mind. Then he covered his OS and used his OD to look at the adjacent adjustable-color box in column 2: he changed the color displayed in this box so that its color matched the memorized color perceived by the OS looking at the fixed-color target box in column 1. This adjustment process is shown in Fig. 5. This was repeated dozens of times: with this technique, the subject looked *alternately* with his OD, then his OS, then his OD, then his OS, etc.




Figure 4. The first technique (called *alternative viewing*) for matching perceived colors on a computer monitor. The four colored squares of column 1 were made two centimeters per side and were presented 57.3 cm from the subject's eye, thus they subtended two degrees of visual angle. The subject adjusted the colors of column 2 to match his left eye's perceived colors. The HSL color parameters of column 1 are, from top to bottom, red 0, 240, 106; green 80, 240, 106; blue 160, 240, 106; and yellow 40, 240 106.

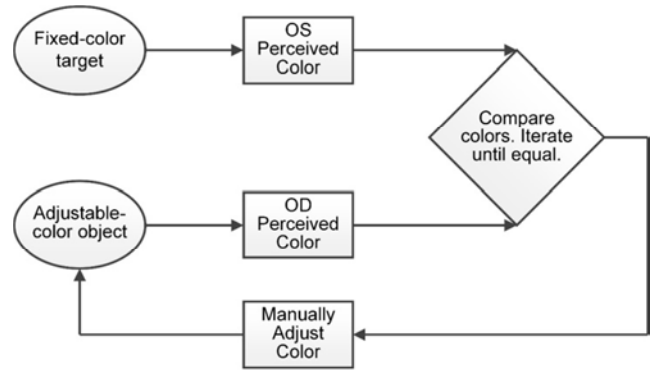


Figure 5. Process diagram for modifying an adjustable-color object. The subject compares OS the perceived color of a fixed-color target (like column 1 of Fig. 4) to the OD perceived color of an adjustable-color object (like column 2 of Fig. 4), and then the subject adjusts the color of the adjustable-color object to make them match. The perceived color boxes contain the systems to be presented in Fig. 10.

The second technique for matching perceived colors allowed *simultaneous* viewing with the two eyes. The subject has strabismus, because of the scleral buckle implanted during his first detached retina operation. So, at rest, the image seen by his OS drifts about ten degrees to the right for a target at 57.3 cm. With this technique, columns 1 and 2 were presented on the monitor. The subject relaxed his eyes allowing the OS to diverge to its rest position. His OD then saw columns 1 and 2 and simultaneously his OS saw columns 1' and 2', which had drifted to the right as shown in Fig. 6. He then adjusted the color of the adjustable-color box in column 2 so that it matched the OS perceived color in column 1'. This technique could not be used for targets larger than five degrees, because the rest point disparity is only ten degrees (at a viewing distance of 57.3 cm). In addition, the assessment had to be made within five to ten seconds, before the OS images faded out.

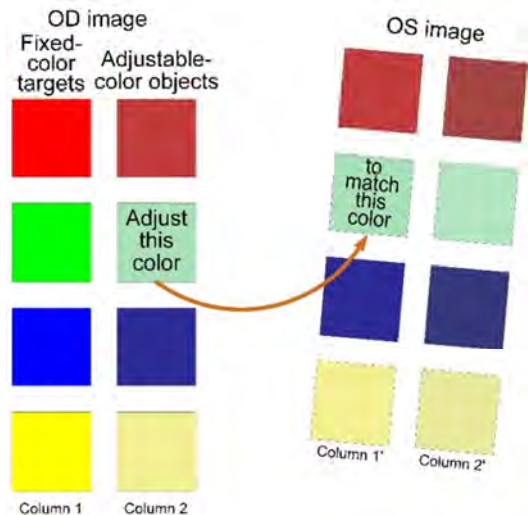


Figure 6. The second technique (called *simultaneous viewing*) for matching perceived colors. Columns 1 and 2 were presented on the monitor. The subject relaxed his eyes allowing the OS to diverge to its rest position. His OD then saw columns 1 and 2 and simultaneously his OS saw columns 1' and 2'. He then adjusted the color of the adjustable-color box in column 2 so that it matched the OS perceived color in column 1'.

The perceived color of a visual target depends on the size of the target [12]. The next experiment had 24 circular targets: there were the six colors of red, yellow, green, cyan, blue, and magenta with four diameters of one, five, ten and twenty degrees, corresponding to areas of the retina named, respectively, the clinical fovea, the clinical macula, the parafovea and the perifovea (see Table 1). For the 20 and 10-degree diameter disks, the subject used the first technique (alternate viewing) for matching perceived colors. For the five and one-degree disks, he used the second technique (simultaneous viewing). (Although the results were the same when he used the alternate viewing technique.) For these disks, he relaxed his eyes and allowed his eyes to diverge. Then he looked at the adjustable-color object with his OD and adjusted its color to match the color perceived by his OS, which was looking at the fixed-color target. Then a target with a different size or color was assessed: This was repeated hundreds of times. Finally the two dozen OS perceived-color disks were combined with the target disks (with a nonlinear size mapping) to produce Fig. 7.

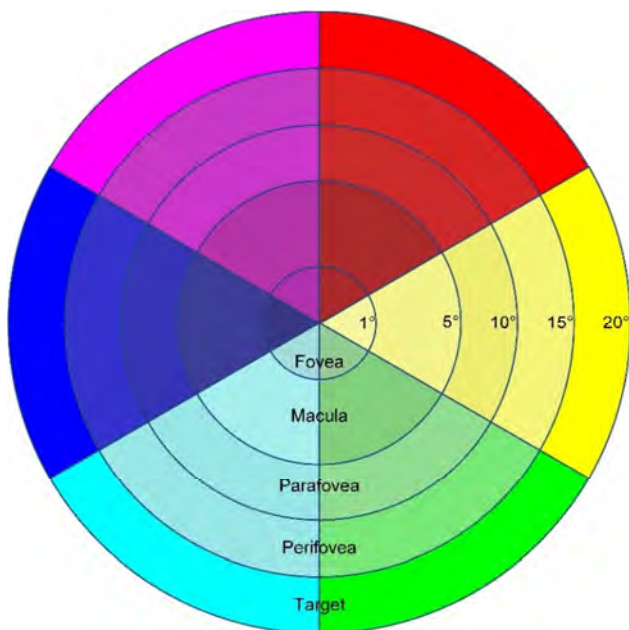


Figure 7. The subject's color-vision deficiency depends on the size of the target. This figure does not conserve linear scale: which means, for example, that the ten-degree ring in this figure is not twice the size of the five-degree ring. The outside ring shows the target colors. The rest of this disk shows the left eye perceived colors. The perifoveal ring shows the OS perceived colors for the target disks that were 20 degrees in diameter. The parafoveal ring shows the OS perceived colors for the 10-degree target disks. The macular ring shows the perceived colors for the 5-degree target disks. Finally, the foveal disk shows the perceived colors for the 1-degree target disks. The colors shown here are different from those shown in Figs. 2 and 3. For example, the color of the green wedge inside the fovea is not white. The reason for this is that the targets were larger in this figure.

Figure 7 shows what the OS perceived. In the blue wedge, the perceived saturation and luminance decreased monotonically from the outside ring to the center of the disk. (The printed journal pages might not show these

gradations.) We can generalize that the OS perceived the colors of red, blue and magenta, the colors with a small green component (average RGB green component values of 50 out of 255), as darker than the targets and they got darker from the outside ring to the center. Whereas, the OS perceived colors of yellow, green and cyan, the colors with a large green component (average RGB green component values of 230 out of 255), as lighter than the targets. This figure and a plethora of backup data indicate that the perceived color depends on the size and hue of the targets. This was true for any background or shape of targets.

The color of the foveal part of the green wedge of Fig. 7 is a good match to the color of the clinical fovea of Fig. 3, given that the target for Fig. 7 was a one-degree disk of unsaturated green light, while the target for Fig. 3 was a 0.07-degree dot of saturated green laser light.

Figure 5 showed the subject's technique for matching colors displayed on a monitor. It used the human color vision system model to be presented in Fig. 10. Here is a qualitative synopsis of a quantitative simulation of this model, which is described in another paper. The purpose of this next paragraph is to show that the technique and experimental data are consistent with the opponent-process model.

One of the communication channels of the opponent-process model is the *red minus green channel* of Fig. 10. When the subject looked at a pure green target with his green-deficient OS, according to the opponent-process model, his OS *red minus green channel* may have had less green inhibition than the OD channel and therefore the OS channel output signaled more red (less green) than the OD channel. The OS and OD channel outputs were different and the subject needed to make them match. He might have started by reducing the green in the adjustable-color object of Fig. 4. However, he also saw that the OS perceived color was less saturated. Increasing the red in the adjustable-color object would make its color less saturated and also augment the previous reduction in green. Therefore, as an interim solution, he might have reduced the green and increased the red in the adjustable-color object. This gave him a new starting point and the process repeated.

In summary, this section has shown that the subject's color-vision deficiency depends on the color (wavelength) of the target (Fig. 2), position on the retina (Fig. 3) and the size of the target (Fig. 7). This means that the damage to the subject's retina is not uniform, it is greater in the central part of the retina and it is heterogeneous in that it affects green more than red or blue. This section has also shown that the process and experimental data are consistent with the opponent-process model.

3.4. Afterimages

If a person with normal color vision stares steadily at the black dot on the Swedish flag of Fig. 8 for about 30 seconds and then moves his or her gaze to the white area to the right,

after a couple of seconds an afterimage appears with complementary colors: that is, for a few seconds the afterimage will look like a blue cross on an orangish-yellow background. Analogous effects occur for the Italian flag on the right, with the red part becoming its complementary color, cyan, and the green part becoming its complementary color, magenta. The subject's normal OD perceives these afterimages as described, but his damaged OS sees no afterimages for small targets. Additionally, on the provisional 'flight of colours' test examining afterimages [13], the OD scored good and OS scored poor to fair. All afterimage effects depend on the duration of viewing and the steadiness of fixation. Voluntary suppression of microsaccades enhances the effect. Whereas, blinks and head movements attenuate the effects.



Figure 8. Targets for inducing negative-color afterimages. If you stare at the black dot on the Swedish flag for about 30 seconds, then move your gaze to the white area to the right. After a couple of seconds, an afterimage will probably appear with complementary colors: that is, for a few seconds the afterimage will look like a blue cross on a yellow background, which might drift around. The afterimage of the Italian flag will have colors of, from left to right, magenta, gray and cyan.

The negative-color afterimages of Fig. 8 are often explained with fatigue (or saturation, or adaptation) of *retinal cones*, although there are other explanations [14]. For example, for the fatigue explanation, a steady green light will fatigue green retinal cones. Then when viewing a white background (blue plus green plus red equals white) the brain perceives it as white with the green removed (because the green cones are nonresponsive) leaving blue plus red, which is magenta. However, this fatigue explanation, which is based on the trichromatic model for the retina, does not work well for blue and yellow, because humans do not have yellow cones.

Young's [1802] trichromatic model of color perception

postulated three types of visual receptors, that he named blue, green and red. However, the spectral responses of these three cone types do not peak at exactly blue, green and red (See Fig. 9). Therefore, people often refer to them as short wavelength sensitive (SWS) cones, medium wavelength sensitive (MWS) cones and long wavelength sensitive (LWS) cones, or simply S-cones, M-cones and L-cones.

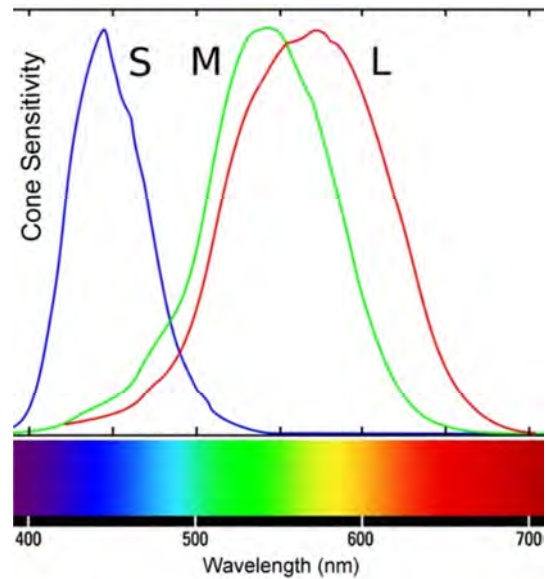


Figure 9. Normalized sensitivity of human short (S), medium (M) and long (L) wavelength retinal cone types (top) and the color spectrum for normal daylight (bottom) both as functions of wavelength. The cone sensitivity curves in this figure (and the cone icons in figure 10) are colored blue, green and red for heuristic reasons: these colors represent neither the colors of the cones nor the colors to which they are sensitive.

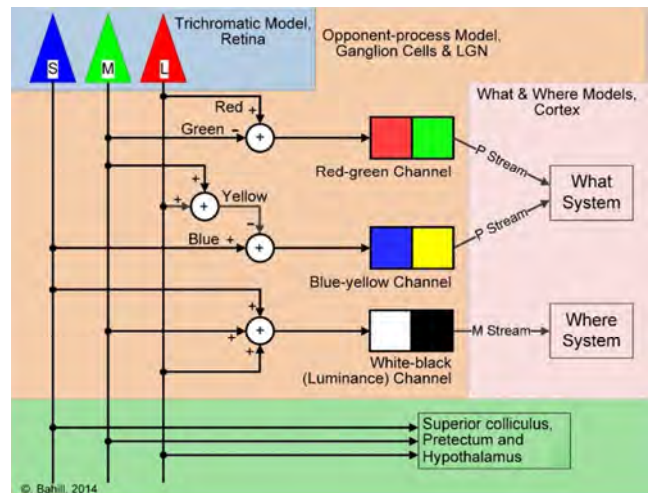


Figure 10. Model for the human color vision system. The explanation starts with the trichromatic model, in the upper left corner, which explains the signal processing in the retina. Its input is light of varying wavelengths impinging on the S, M and L retinal cones. Its ganglion cell outputs are inputs for the opponent-process model. The neural circuits of the opponent-process model transform its ganglion cell inputs into outputs, which are the red minus green, blue minus yellow and white minus black (luminance) opponent-process channels. Information in these channels is sent to the cortex. One cortical area determines where the object of interest is and another determines what the object is.

To explain negative-color afterimages the opponent-process model must be added to the trichromatic model for the retina, as shown in in Fig. 10. The opponent-process model postulates that the outputs of the retinal photoreceptors are routed to the brain through three color-opponent neural channels: the *red minus green channel*, the *blue minus yellow channel* and the *white minus black channel*. When one of the colors of a channel is “fatigued,” by staring at an object of that color, that object will be perceived in its complementary color. For example, if you stare at a yellow object for around 30 seconds, the neuronal circuits that produce the sensation of yellow become “fatigued.” Which means that they no longer inhibit the *blue minus yellow channel*. Without this inhibition, the blue cells predominate and the brain perceives blue. The *red minus green channel* and the *white minus black channel* behave in a similar manner. The subject of this paper does not experience these negative-color afterimages in the fovea of his OS: this is consistent with loss of foveal retinal ganglion cells.

The subject’s lack of afterimages is primarily foveal. When the flags of Fig. 8 were two degrees wide (or smaller), the subject’s OS saw no afterimages. When Fig. 8 was close to the eye so that the flags were 20 degrees wide, the OS saw faint afterimages. For example, when he stared monocularly at the Swedish flag for more than 60 seconds, and then looked at a plain white background, after about a second and for a second or two the subject saw a faint blue cross, about one-tenth the intensity of the OD. This dependency on the size of the target was similar to Fig. 7. For a 40-degree wide flag, the subject saw the blue cross. This suggests that the subject’s color-vision deficiency is restricted to ganglion cells that received inputs from the fovea, not the periphery.

4. Discussion

4.1. Origin of This Color-Vision Deficiency

The following is a synopsis of the subject’s ocular history as it was presented by Bahill and Barry [5]. First, the historical sequence of events will be used to rule out possible causes of the color-vision deficiency: detached retina with macula off, June 30 2008; peeling of the inner limiting membrane (ILM), October 20, 2009; first experiments and documentation of macular scotoma, November 2, 2009; first experiments and documentation of the color-vision deficiency, November 5, 2010.

History rules out three possible causes, because they occurred more than a year before the color-vision deficiency became manifest. His strabismus and diplopia started after a detached retina operation in May 2008: this is too early to be a cause of the color-vision deficiency. The resulting headaches, probably caused by a continual retinal induced asthenopia due to the excyclorotation, might have caused the brain to suppress vision (amblyopia) in the OS by about a log unit. However, amblyopia is not known to be heterogeneous across position and wavelength.

The wrinkled retina (shown in Fig. 1) started after the

macula-off detached retina in June 2008. This macula-off detachment and subsequent operations could not have damaged the retinal photoreceptors and caused this color-vision deficiency because the color-vision deficiency did not start until the fall of 2009.

Retinal scar tissue caused by cryopexy and laser photocoagulation started in the summer of 2008. Again, this is too early for it to be a cause of the color-vision deficiency. Furthermore, the subject’s foveal color-vision deficiency is not due to photocoagulation, because this scar tissue is all in the periphery as shown in the fundus photo of Fig. 11. Note: the subject is myopic, which explains the myopic crescent around the optic disk.

In summary, none of these three events is a likely cause for the color-vision deficiency, because they all happened more than a year before the color-vision deficiency became manifest.

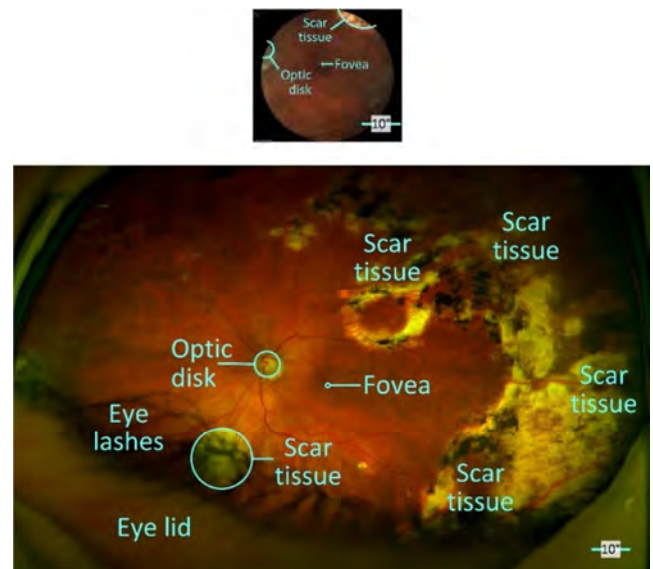


Figure 11. Fundus photo (top) and Optomap photo (bottom) of the left retina. The Optomap image has bigger field of view, but it is nonlinear. Scar tissue is in the periphery.

The macular scotoma (shown in Fig. 1) was created in October 2009 while peeling the ILM. The color-vision defects were also found after that surgery. At first, the defects were a puzzlement, like the small green dot of light produced by a tonometer appearing white. Then evidence accumulated more frequently. The subject performed experiments and finally documented the color-vision deficiency [5].

The defect is located in the pathway between the photoreceptors and the cortex. Referring back to Fig. 3 and the experiments it is based on, the circle inset in the lower-right corner shows the appearance of the four laser dots when they were simultaneously aimed at the area of the target that stimulated the inferior-nasal region of the clinical fovea of the OS. For the most part, the perceived red, blue and yellow dots had appropriate hues but unsaturated colors; however, the green dot was perceived as white. This makes it unlikely that the color-vision deficiency is due to destruction of retinal cones, because in this small region of the fovea, there must

be green cones in order to produce the perception of yellow {see Fig. 10}. Therefore, the visual deficit must be higher in the visual system than the photoreceptor layer, perhaps in the optic nerve, which is composed of the axons of the retinal ganglion cells that are connecting to cells of the lateral geniculate nucleus (LGN). It is unlikely that the deficit is higher in the visual system than the LGN, because the deficit is strictly monocular. Therefore, the deficit could have been caused by destruction of retinal ganglion cells (particularly in the *red minus green channel* of Fig. 10) or compression of the optic nerve. However, intraocular pressures have consistently averaged 13 mm Hg for the last eight years, two magnetic resonance images failed to detect abnormalities in the eyes or optic chiasm and a dozen OCTs have shown no obstruction at the optic disk.

A macula-off detached retina could disturb the photoreceptor layer and destroy S-cones producing tritan-like color discrimination deficits [8, 9, 10]. Figure 12 shows that is not likely in this case. The left column of Fig. 12 has the targets. The HSL coordinates are {Hue, 240, 120}. The second column shows what a tritanope would see. These colors were created by removing the blue from column 1. The tritanope cannot distinguish between pink and orange (second and third rows) or between cyan and green (bottom two rows). The results for our subject shown in column 3 and 4 are not those of a tritan.




Figure 12. The colored squares in the left column were presented on a computer monitor 57.3 cm from the subject's eye. The RGB color parameters are, from top to bottom, magenta 255, 0, 255; pink 255, 175, 200; orange 255, 175, 0; yellow 255, 255 0; green 0, 255, 0; and cyan 0, 255, 255. The second column simulates what a tritanope would see: these colors were created by removing the blue from the left column. The tritanope cannot distinguish between pink and orange or between cyan and green. The colors in the third and fourth columns show what our subject perceived when the targets subtended 0.5 and two degrees of visual angle.

In summary, these measurements and experiments have ruled out many possible causes for this subject's color-vision deficiency, such as (a) genetics, (b) insertion of the scleral buckle and subsequent diplopia, (c) suppression of OS vision (amblyopia) in order to reduce the asthenopia headaches caused by the wrinkled retina and the cyclorotational disparity, (d) damage to the retinal photoreceptor layer, and (e) scar tissue caused by laser photocoagulation. This leaves as the primary candidate destruction of retinal ganglion cells while peeling the ILM.

4.2. Capabilities of Existing Instruments

In this section, we will evaluate the ability of existing ophthalmological and optometric instruments to measure, document and explain this subject's macular scotoma and acquired foveal color-vision deficiency.

When the subject was restricted to four seconds per line, the Snellen test of visual acuity suggested a scotoma or a wrinkled retina. Otherwise, when the subject was given a lot of time, he would saccade obliquely across the letters and pick them up with off-foveal vision. The Snellen test is achromatic, therefore, it could not disclose the color-vision deficiency.

Visual field tests use a bright white target on a dull white background. They are achromatic and, therefore, they cannot help with the color-vision deficiency. However, visual field tests should reveal the scotoma, although, it took eight years to document the scotoma with visual field tests. The initial visual field tests were 24-2 and they did not detect the scotoma. The first half-dozen 10-2 visual field tests also missed the scotoma. Finally, in 2016, with specific instruction, visual field tests with two different instruments revealed the foveal scotoma.

One hundred and fifty slit lamp views, a dozen fundus photos, many Optomap images and three dozen optical computed tomography (OCT) images showed no anatomical abnormalities in the region of this macular scotoma. Furthermore, two magnetic resonance image (MRI) scans failed to detect anatomical abnormalities in the eyes, optic chiasm or visual cortex.

Colorblindness tests administered in optometrist and ophthalmologist offices also failed to find these deficiencies. They were administered binocularly and they used large visual fields. Could they be adapted? If the doctors were told in advance that the subject had a color vision abnormality in the fovea of his OS, could they detect it? The Ishihara test worked for targets covering two degrees of visual angle. For smaller targets, their resolution was too poor for even the OD to recognize patterns. If the instructions for the Hardy-Rand-Rittler (HRR) pseudoisochromatic plates were modified to instruct monocular viewing of one or two degree targets, then they could detect these color vision abnormalities. If the instructions for the X-Rite color IQ test (Farnsworth-Munsell 100 Hue Test) were modified to instruct monocular viewing it could detect the color-vision deficit.

The following questions will be addressed in Table 3. When the doctors were told in advance that the subject had a

scotoma in the lower-left part of his OS macula, would the test or instrument be able to confirm it? When the doctors were told in advance that the subject had a color vision

abnormality in his OS fovea, would the test or instrument be able to confirm it? What modifications to their standard test procedures would be necessary to confirm it?

Table 3. Capabilities of existing instruments.

	Could they confirm the scotoma?	Could they confirm the color-vision defect?	What major modifications would be needed?
Snellen test	fuzzy	no	not possible
Visual field tests	after eight years, yes	no	not possible
Slit lamp, fundus photos and OCT	no	no	not possible
Ishihara plates	no	yes	Administer monocularly and control distance to and size of the targets
Hardy-Rand-Rittler plates	no	yes	Administer monocularly and control distance to and size of the targets
X-Rite color IQ test (Farnsworth-Munsell)	no	yes	Administer monocularly and control distance to the targets
The tests in this paper	yes	yes	none

Therefore, existing tests could be modified to detect the subject's OS color-vision deficiency. However, none of them could describe this deficiency with the detail of figures 2, 3, 4 and 6. Only two of the existing tests could confirm the scotoma, but not with the resolution of figure 1.

4.3. Visual World

Of course, the subject's perception of the visual world is not as debilitating as the figures in this paper might suggest, because vision in his OD, peripheral vision of the OS, feeble foveal color vision in OS and most importantly neural *filling-in* [16] give the brain enough clues to compute a reasonable visual environment. A ten-degree green disk looks like a green disk, not like a green donut. This is analogous to normal subjects being unaware of the blind spots in their visual fields caused by their optic disks.

This cortically computed visual environment is the reason that large-area targets, as used in most color-vision tests, cannot be used to detect small-area defects. Figures 2 and 3 show that small-area laser dot targets can expose these deficiencies, but the outside rings of Fig. 6 shows that large-area targets cannot detect these deficiencies.

5. Conclusion

Detached retinas and subsequent surgeries produced retinal blindness (the scotoma) in the lower-left octant of the macula of the subject's OS visual field (Fig. 1) and color-vision deficiency in some other areas of the macula (Fig. 3). When the visual targets were made small, the Hardy-Rand-Rittler pseudoisochromatic plates and the Farnsworth-Munsell 100 Hue Test concluded that he was color deficient in the fovea of the left-eye. Using small dots of laser light, showed that the areas of color-vision deficiency were different from the scotoma, although both were probably caused by peeling the ILM. These experiments showed that, to the fovea of the OS, the red laser dot appeared pink (unsaturated red), the green laser dot appeared white, the blue laser dot appeared bluish-white, and the yellow laser dot appeared yellowish-white. Position on the retina also had a big effect on the perceived color, with the fovea showing the biggest deficits (Fig. 3). Furthermore, his perceived color depended on the size of the

target: 20-degree targets appeared almost normal (Fig. 7) and 0.1-degree targets were almost colorless (Fig. 2). Additionally, the colored laser lights added as expected: for example, when the red and green lasers were superimposed, the resultant was perceived as yellow by the OD and as white by the OS. Peculiarly, the OS did not perceive negative-color afterimages.

Most commercial color-vision deficiency tests use large target images. Using these tests ophthalmologists and optometrists were not able to detect and document the acquired color-vision defects in the clinical fovea of the subject's OS. In contrast, this paper has explained a new color-vision-deficiency test system that did detect these small areas of color-vision deficiency. This test system used two distinctly different types of targets (a) lasers that produced small targets, with diameters of 0.07 degrees of visual angle (Figs. 2 and 3) and (b) computer monitors that presented targets with diameters of one to twenty degrees (Figs. 4, 6 and 7). Both showed gradients in the degree of color-vision deficiency.

The subject has an acquired anomalous color perception deficiency. Existing ophthalmological instruments, commercial color-vision tests and nomenclature in the literature were inappropriate for the subject. Our test system has mapped his color perception deficiency with respect to the location on the retina, type of deficiency, anatomical location of the destruction and the target's size and color.

Acknowledgements

For helpful comments on the manuscript, I thank members of the Systems Engineering Brain Trust: Bruce Gissing, Bob Sklar and Jerrold Swain. I thank Lawrence Jones Esq. for legal advice. The subject (the first author) has given his informed consent for this report to be published.

Abbreviations

CMYK	Cyan, Magenta, Yellow, black
$B - Y$	Output of the blue minus yellow opponent-process channel
ILM	Inner limiting membrane ILM
IOP	Intraocular pressure IOP

L	Long wavelength, 565 nm
LGN	Lateral geniculate nucleus LGN
M	Medium wavelength, 535 nm
OD	Right eye
OS	Left eye
RGB	Red, Green, Blue
$R - G$	Output of the red minus green opponent-process channel
S	Short wavelength, 420 nm

References

- [1] Daniel (2016) Color Blind Essentials, www.colorblindness.com Accessed September 2, 2016.
- [2] Wagner BT and Kline D (2016) The Bases of Colour Vision, University of Calgary, <http://psych.ucalgary.ca/PACE/VA-Lab/Brian/default.htm> Accessed September 2, 2016.
- [3] Jafarzadehpur E, Hashemi H, Emamian, MH et al. (2014) Color vision deficiency in middle-aged population: the Shahroud eye study, *Int Ophthalmol* 34: 1067-1074. doi:10.1007/s10792-014-9911-2.
- [4] Bahill AT and Barry PJ (2014) Multimodal views of the human retina. *Ophthalmol. Res. An International J.* 2 (3): 126-131.
- [5] Bahill AT and Barry PJ (2014) A patient's viewpoint of cataract and retinal detachment surgeries, *Ophthalmol. Res. An International J.* 2 (6): 294-324.
- [6] Tadayoni R, Svorenova I, Erginay A, Gaudric A and Massin P (2012) Decreased retinal sensitivity after internal limiting membrane peeling for macular hole surgery. *Br. J. Ophthalmol.* 96 (12): 1513-1516. doi:10.1136/bjophthalmol-2012-302035.
- [7] Poon WKM, Ong GL, Ripley LG and Casswell AG (2001) Chromatic contrast thresholds as a prognostic test for visual improvement after macular hole surgery: color vision and macular hole surgery outcome. *Retina.* 21 (6): 619-626.
- [8] Simunovic MP (2016) Acquired color-vision deficiency, *Survey of Ophthalmology*, Volume 61, Issue 2: 132-155.
- [9] Pacheco-Cutillas M, Edgar DF and Sahraie A (1999) Acquired colour vision defects in glaucoma—their detection and clinical significance, *Br J Ophthalmol*; 83: 1396-1402 doi:10.1136/bjo.83.12.1396.
- [10] Nork TM (2000) Acquired color vision loss and a possible mechanism of ganglion cell death in glaucoma. *Trans Am Ophthalmol Soc* 98: 331-363.
- [11] Cole BL, Lian KY and Lakkis C (2006) The new Richmond HRR pseudoisochromatic test for colour vision is better than the Ishihara test. *Clinical and Experimental Optometry*, 89: 73-80. doi:10.1111/j.1444-0938.2006.00015.x.
- [12] Smith VC and Pokorny J (2003) Color matching and color discrimination, Chapter 3 in *The Science of Color*, ISBN 0-444-512-519, Elsevier Ltd.
- [13] Feldman M, Todman L and Bender M (1974) 'Flight of colours' in lesions of the visual system. *J. Neurology, Neurosurgery, and Psychiatry.* 37: 1265-1272.
- [14] Bridgeman B, Winter D and Tseng P (2010) Dynamic phenomenology of grapheme-color synesthesia. *Perception.* 39: 671-676.
- [15] Bradtmiller B, Hodge B, Kristensen S and Mucher M (2008) Anthropometric Survey of Federal Aviation Administration Technical Operations Personnel, Federal Aviation Administration, Washington, DC 20591.
- [16] Krauskopf, J (1963) Effect of Retinal Image Stabilization on the Appearance of Heterochromatic Targets, *J. Opt. Soc. Am.* 53, 741-744 <https://www.osapublishing.org/josa/abstract.cfm?URI=josa-53-6-741> Accessed 25 Aug 2016.